

Maxillofacial surgery in wartime Middle-East: Paul Tessier's missions to Iran

Quentin **Hennocq**, MD¹; Amin **Bennedjaï**, MD¹; François **Simon**, MD²; Sylvie **Testelin**, MD PhD³;
Bernard **Devauchelle**, MD PhD³; Jean-François **Tulasne**, MD⁴; Stéphanie **Dakpé**, MD³; Hossein **Khonsari**,
MD PhD¹

¹Assistance Publique — Hôpitaux de Paris, Hôpital Necker — Enfants Malades, Service de Chirurgie Maxillo-Faciale et Plastique, Université Sorbonne Paris Cité, Université Paris Descartes, Paris, France

²Assistance Publique — Hôpitaux de Paris, Hôpital Necker — Enfants Malades, Service d'Oto-Rhino-Laryngologie et Chirurgie Cervico-Faciale, Université Sorbonne Paris Cité, Université Paris Descartes, Paris, France

³Service de Chirurgie Maxillo-Faciale, Centre Hospitalier Universitaire Amiens-Picardie, Amiens, France

⁴26 avenue Kléber, 75116, Paris, France

Corresponding author:

Quentin Hennocq, MD

Service de Chirurgie Maxillo-Faciale et Plastique, Hôpital Necker — Enfants Malades

149 rue de Sèvres, 75015 Paris, France

Email: quentin.hennocq@aphp.fr

Maxillofacial surgery in wartime Middle-East: Paul Tessier's missions to Iran

SUMMARY

The Iraq-Iran war (1980–88) resulted in numerous maxillofacial injuries. More than 400,000 people were wounded and required specialist care. Paul Tessier, a leading French plastic surgeon and pioneering craniofacial surgeon, was involved in several missions to Iran and operated on a vast cohort of patients with complex war trauma sequelae.

Our study included 322 files relating to patients with war injuries operated on by Paul Tessier in Iran from 1990 to 1993. The files are the property of the Association Française des Chirugiens de la Face. Relevant epidemiological parameters and data on surgical indications and procedures were collected. Descriptive statistics were used in order to characterize the cohort, and a multivariate logistic model used to assess factors associated with severe eye injuries within all facial injuries.

Age range at admission was 5–67 years (average: 27.15 ± 6.97). The most common trauma mechanisms were shell fragments (161 patients; 50 %) and bullets (27 patients; 8.38 %). The bone and orbital contents in the upper third of the face were affected in 124 patients (38.50%); 72 patients (22.36%) had trauma of the middle third of the face; and 86 patients (26.71%) had trauma of the lower third. A total of 175 bone grafts were harvested by Tessier: 72 (41.14%) iliac grafts and 94 (53.71%) frontal and/or parietal grafts. Tessier managed 60 orbital fractures (18.63%) and 95 patients with uni- or bilateral enucleations (29.50%). A multivariate logistic model showed that patients injured by shells were 4.04 (1.32; 17.60) more likely ($p = 0.03$) than patients with gunshot wounds to have had uni- or bilateral enucleation, regardless of age and gender.

Tessier's files provide first-hand information on the injury patterns that resulted from a regional war in the 1980s, and on the reconstruction challenges faced by a country during its post-war recovery period.

Keywords: war injuries; ballistic trauma; Iraq-Iran; facial reconstruction; war surgery

INTRODUCTION

In addition to the 200,000–600,000 casualties, more than 400,000 people — both soldiers and civilians — were injured on the Iranian side between 1980 and 1988 during the Iraq-Iran conflict (*Khosravi and Akhavan, 2015*). Figures were of the same order of magnitude on the Iraqi side (*Khosravi and Akhavan, 2015*). According to Carey (*Carey, 1991*), among the American armed forces in Iraq, 17.3% received head wounds, 4.3% neck wounds, 5.8% chest wounds, 9.3% abdominal wounds, and 90% extremity wounds.

Maxillo-facial injuries were frequent, as in most 20th-century conflicts. Several public health studies have noted an increase in the proportion of maxillofacial injuries in the 20th and 21st centuries in American and British armies, probably due to an improvement in chest and abdomen protection devices and the more common use of explosive weapons (*Khosravi and Akhavan, 2015*).

Paul Tessier (1917–2008) was a French plastic surgeon and a pioneer of craniofacial surgery (*Wolfe, 1997*). Tessier took part in several missions to Iran, supported by the JAO (Janbazan Affairs Organization). Jean-François Tulasne (Paris, France), David Matthews (Charlotte, USA), Joe Murray (Boston, USA), Fernando Ortiz Monasterio (Mexico City, Mexico), Yvon Raulo (Paris, France), and Luigi Clauser (Ferraro, Italy) were part of the international team of surgeons that travelled to post-war Iran in order to operate on facial injuries with Tessier.

The purpose of Tessier's missions to Iran was to provide advanced reconstructive surgery to patients with facial war injuries. Eiseman (*Eiseman, 1979*) defined four types of war according to their spatial extent: (1) terrorist attacks, (2) rural attacks, (3) minor conventional wars, and (4) major conventional wars. The Iraq-Iran conflict was classed as a minor conventional war (type

3). Maxillofacial trauma is more common in conflicts with small spatial extent: 21% of injuries in terrorist attacks are maxillo-facial, as opposed to 15% in major conventional wars (*Dobson et al.*, 1989). The face is also easily targeted by small arms and light weapons, and facial protective devices are often lacking in small conflicts.

We collected 322 files on patients with facial war injuries who were operated on by Paul Tessier in Iran from 1990 to 1993, as part of international surgical missions involving a team of prominent plastic surgeons. These files were the property of the *Association Française des Chirurgiens de la Face* and are part of the *Tessier Collection*, stored in the University Hospital of Amiens, France. We collected epidemiological parameters and details on surgical procedures. Descriptive statistics were used to characterize the cohort, and a multivariate logistic model to assess the factors associated with severe eye injuries within all facial injuries.

METHOD

The files of 322 patients managed by Paul Tessier in Tehran, Iran, between 1990 and 1993, were collected for this study. The variables of interest were: date of assessment, age, date of trauma, gender, injury mechanism (shell fragment, bullet, missile, blast, burn/chemical burn, car accident). The facial lesions were divided into: (1) **upper third skeleton** — including frontal bone and orbits (uni- or bilateral enucleation); (2) **middle third skeleton** — including nasal bones, zygoma, maxilla and alveolar bone, maxillary sinuses, and hard palate; (3) **lower third skeleton** — including the mandible, the temporo-mandibular joint (TMJ); (4) **occlusal disorders**; and (5) **soft tissue damage** — including tear ducts, eyelids, nose, lips, ears, and burn scars. The number of reconstructive surgery procedures and the country in which they were performed were recorded. The number of procedures involving a bone graft and/or a flap was noted. The types of procedure were as follows: (1) bone and/or costal grafts; (2) foreign body removal; (3) dental implant placement; (4) orthognathic surgery; (5) TMJ ankylosis surgery; (6) uni- or bilateral canthopexy; (7) lip surgery — modeling cheiloplasty, vestibuloplasty, Abbé flap; (8) orbital cavity refection — prosthetic rehabilitation after enucleation; and (9) local plastic procedures — local advancement or rotation flaps, Z/W/V–Y plasties, excision of hypertrophic scars, rhinoplasty, expander placement, tear duct surgery, otoplasty, and regional flaps — temporal, Abbé, Baron-Tessier, scalp, other regional flaps, free flap. Among the bone and/or costal grafts, the harvest site was noted when available (iliac, frontal and/or parietal, temporal osteo-muscular flap, or costal), as well as the receiver area (frontal, including the anterior wall of the frontal sinus and the upper rim of the orbit; orbits, including the lateral and medial walls and the floor of the orbit; the nasal dorsum; the zygoma, including the lower edge of the orbit but not the orbital floor; the maxilla, including the alveolar bone, the anterior wall of the maxillary sinus

and the hard palate; and, finally, the mandible. The orthognathic procedures were: Le Fort I osteostomy, sagittal split of the mandible, and genioplasty. Epithelial inlays or total skin grafts for vestibuloplasties and orbital cavity reconstructions were noted, as well as conformer placements and pseudorrhaphy for orbital cavity repair. Bone grafts, septoplasties, and conchal cartilage grafts associated with rhinoplasties were recorded. Complications were also considered: infection, graft pseudarthrosis, graft necrosis, bleeding, and other complications.

A multivariate logistic model was used to assess the statistical relationship between enucleation and injury mechanism in victims of shell fragment and bullet trauma. The age and gender variables were integrated into the model in order to eliminate potential confusion factors. The hypotheses of normality and homoscedasticity of the residues were tested. The parameters were compared with 0 using a Student test, and a value of $p < 0.005$ was defined as a statistically significant relationship. Odds ratios, with their confidence intervals, were computed using these parameters. The statistical analyses were performed using *R* v. 3.3.2 (*R Core Team*, 2016).

RESULTS

Records for 322 patients assessed by Paul Tessier between 1990 and 1993 in Tehran, Iran were collected. 305 (94.72 %) were male, 17 (5.28 %) were female (Table 1). The ages at assessment ranged from 5–67 years (average: 27.15 ± 6.97) (Supp. Fig. 1). The ages at trauma ranged from 2–62 years of age (average: 20.65 ± 7.04). Sixty-eight patients (21.12%) were under 18 years of age at the time of trauma. Trauma occurred between 1971 and 1992 (Figure 2). CT-scans were performed on 54 patients, of which 10 had 3D reconstructions.

Information on injury mechanism was available for 240 patients (74.53%): (1) shell fragments, 161 patients (50%); (2) bullets, 27 patients (8.38%); (3) burns, 21 patients (6.56%) — including three chemical burns (0.93%); (4) blasts, 15 patients (4.66%); (5) missiles, 12 patients (3.73%); and (6) road accidents, 4 patients (1.24%) (Figure 3).

The deep structures of the upper third of the face were affected in 124 patients (38.50%), compared with 72 (22.36%) for the middle third and 86 (26.71%) for the lower third (Figure 4, Supp. Fig. 2). Injuries of the upper third of the face included 13 frontal fractures (4.04%), 60 orbital fractures (18.63%), and 95 uni- or bilateral enucleations (29.50%). Injuries of the middle third of the face included 18 nasal bone fractures (5.59%), 29 zygomatic fractures (9.01%), and 35 maxillary fractures (10.87%). Injuries of the lower third of the face included 36 mandibular body fractures with pseudarthroses (11.18%), 15 TMJ ankyloses (4.66%), and 12 occlusal abnormalities (3.73%). Other more superficial lesions affected 136 patients (42.24%): 39 uni- or bilateral eyelid injuries (12.11%), 32 lip injuries (9.94%), 18 nasal mutilations (5.59%), 18 burn injuries (5.59%), eight tear duct lesions (2.48%), and three ear mutilations (0.93%).

Patients seen by Tessier and his team had previously benefited from 0–40 surgeries (average:

6.22 ± 7.25). This information was available for 211 patients (Supp. Fig. 3). Of these surgeries performed before Tessier's missions, 171 procedures had been performed in Iran, 34 in Germany, five in the UK, two in Spain and one in each of the following countries: France, Jordan, Turkey, Australia, Iraq, and Austria. During these previous procedures, 46 bone grafts had been performed, and 28 flaps (local or free flaps).

Paul Tessier himself used bone grafts extensively for facial reconstruction. A total of 175 grafts were harvested, of which 72 (41.14%) were iliac grafts, 94 (53.71%) frontal and/or parietal grafts, seven (4.00%) temporal osteomuscular flaps, and two (1.14%) rib grafts (Figure 6). A total of 198 grafts were performed (one harvested graft could be used in several sites): 13 (6.57%) grafts in the frontal area, 58 (29.29%) periorbital grafts, 26 (13.13%) nasal grafts, 28 (14.14%) zygomatic grafts, 36 (18.18%) maxillary grafts, and 37 (18.69%) mandibular grafts (Figure 6). The other procedures performed by Tessier were: 65 uni- or bilateral canthopexies and 61 orbital cavity reconstructions; 58 local flaps (advancement flaps, rotation flaps or V, V-Y, W, or Z plasty) and 53 regional or free flaps; 34 lip surgeries (commissuroplasties and/or vestibuloplasties); 28 rhinoplasties; 24 removals of foreign bodies; 22 expander placements; 19 dental implant placements; 15 orthognathic procedures, including four Le Fort I osteotomies, two sagittal splits of the mandible, and nine genioplasties; 11 TMJ ankylosis surgeries (temporal aponeurosis flap after ankylosis block resection); nine tear duct surgeries; and two otoplasties (Figure 5).

The vestibuloplasties (28) involved an epithelial inlay in six cases (21.43%) and a total skin graft in 10 cases (35.71%). Orbital cavity reconstructions used an epithelial inlay in 20 cases (32.79%) and a total skin graft in 27 cases (44.26%). An intra-orbital conformer with pseudorrhaphy was used in 31 patients (50.82%) and pseudorrhaphy alone in 47 patients (77.05%). Rhinoplasty

techniques used by Tessier included 26 bone grafts on the nasal dorsum (92.86%), 14 septoplasties (50.00%), and 11 conchal grafts (39.29%) (Supp. Fig. 4). Tessier performed 53 flaps, including 22 temporal flaps (41.51%), five Abbé flaps (9.43%), seven Baron-Tessier flaps (13.21%), 14 scalp rotation flaps (26.42%), and three free flaps, including one fibula flap, one radial forearm flap, and one tubed abdominal flap (5.66%) (Supp. Fig. 5).

Complications were reported in 25 patients (7.76%): 21 infections (6.52%), four graft mobilities (1.24%), five graft necroses (1.55%), and one case of severe nasal bleeding (0.31%). A perioperative death due to an anesthetic accident was also reported (Supp. Fig. 6).

A multivariate logistic model showed that patients injured by shells were 4.039 (1.325; 17.599) more likely ($p = 0.029$) than patients with gunshot wounds to have uni- or bilateral enucleation, at equal age and sex (Table 2, Supp. Fig. 7). The odds ratios for age and sex were not significant, and their confidence interval included 1.

DISCUSSION

Paul Tessier has contributed to the systematization of the management of severe maxillofacial and craniofacial trauma, and his work on complex fractures and ballistic trauma is especially relevant in the context of war-time facial injuries (*Wolfe*, 1997 and 2012). The epidemiology of wartime maxillofacial injuries has been described by Dobson et al. (*Dobson et al.*, 1989) and Eiseman (*Eiseman*, 1979): their overall mean incidence was 16%, which is greater than values based on the ratio of the surfaces of the face to the whole body (12%). The incidence of head and neck injuries was 12% for World War I (1914–18), 9% for the Spanish War (1936–39), 4% for World War II (1939–45), 19% for the war in Northern Ireland (1968–98), and 29% for the Falklands War in 1982 (*Dobson et al.*, 1989). In addition, Breeze et al. (*Breeze et al.*, 2010) found an increasing trend in the proportion of maxillofacial injuries from 2005 to 2007 in British military personnel. We therefore observe an increase in the incidence of maxillofacial lesions, both with time and related to a smaller spatial extent of the conflicts.

Several clinical series reporting the injury patterns of military victims of recent conflicts are available in the literature. Satta (*Satta*, 2003) published a series of 300 Iraqi soldiers operated on for craniofacial lesions: 80.7% were shell injuries, i.e. low-velocity trauma, and 19.3% bullet injuries, i.e. high-velocity trauma. Among all craniofacial lesions, Satta (2003) found 68.3 % facial fractures, including 24.3 % lesions of the middle third of the face and 40.3% mandibular fractures. These authors hypothesized that high-velocity projectiles caused limited entry point lesions and wide exit wounds, with temporary cavitation and a shock-wave effect (*Al-Shawl*, 1986); low-velocity projectiles caused small entry lesions with no exit wound, thus causing much less damage. These results were not in line with our findings, which showed a higher risk of enucleation after low-velocity shell trauma when compared with high-velocity

gunshot wounds. Nevertheless, Satta (2003) had not assessed the specific risk for enucleation and our results were not directly comparable to his. Motamedi and Behnia (*Motamedi and Behnia*, 1999) reported 33 cases of war injury from the Iraq-Iran war, including 70% bullet wounds and 21% shrapnel (shell) wounds, causing 15% periorbital lesions, 39% middle-third lesions, and 45% perioral damage. Reconstructions only used iliac bone grafts. Taher (*Taher*, 1998) reported 1135 war-injured patients treated in Tehran, Iran between 1984 and 1990. In their series, 72.6% of patients had mandibular bone injuries, 36.30% of patients had injuries of the middle third of the face and 20% of patients had injuries of the upper third of the face; 29.4% of all patients had associated eye injuries. The authors reported three main types of ballistic injury: (1) avulsive, (2) penetrating, and (3) perforating. We were able to sort the lesions in our series according to the same three categories: (1) avulsive lesions included soft tissue losses, bone defects, dental losses, and eye enucleation; (2) penetrating lesions encompassed foreign bodies and lesions without an exit orifice; (3) perforating lesions included hard and soft tissue lesions with an exit orifice. Akhlaghi et al. (*Akhlaghi et al.*, 1997) reported the surgical management of 210 war-injured patients in Tehran, Iran between 1981 and 1986. In their series, 20.63% of patients benefited from mandibular bone grafts and 1.59% of patients required orbital reconstruction, with a complication rate of 11.43%, which was higher than the rates reported by Tessier. However, these complication rates were not comparable: Akhlaghi et al. (*Akhlaghi et al.*, 1997) reported acute ballistic trauma cases with a high risk of postoperative infection (foreign bodies, local battlefield conditions, associated burns and blasts), whereas Tessier only practiced secondary surgery distant from the initial trauma.

A series of 43 war-injured patients operated on in Iran by Tessier had previously been reported by Simon et al. (*Simon et al.*, 2015), with a focus on mandibular reconstruction. In this

series, Tessier had performed 24 bone grafts on 19 patients (44%), including 15 iliac grafts and four frontal-parietal grafts; 40% of the injuries were caused by shells and 17% were bullet wounds. The authors described some surgical techniques for which Paul Tessier and his team had developed a specific expertise, such as the Baron-Tessier flap (*Talmant*, 1983 and *Tessier et al.*, 2011) for lower lip and vestibular reconstructions, or the scalp flap for skin loss in zones with facial hair. Tessier systematically applied his principles of craniofacial ‘autarchy’: he considered the head and neck region to be self-sufficient for reconstruction and preferred, for instance, using parietal bone grafts and local/regional flaps, even for complex hard and soft tissue defects (*Wolfe*, 1997 and 2012). These specificities in the management of war injuries were also found in the series we report on.

Single or bilateral enucleation affected 29.50% of patients managed by Tessier in this series. A multivariate logistic model based on this dataset showed that enucleation was not related to age or gender, but only to the type of projectile: shell wounds were about four times more likely to be associated with enucleation than bullet wounds. Shells are in fact low-velocity weapons acting by fragmentation, and are thus associated with a wider range of tissue damage (*Ansell et al.*, 2014 and *Mader et al.*, 2006).

CONCLUSION

Paul Tessier was a pioneering surgeon who applied the same systematic approach to each step of his surgical work (planning, procedure, follow-up). Notably, his conception of craniofacial ‘autarchy’ deserves further attention and investigations: free flaps are nowadays a standard procedure for the reconstruction of complex craniofacial defects, but iliac and fronto-parietal grafts associated with diverse soft tissue reconstruction techniques can still provide a wide range of solutions (*Mertens et al.*, 2014), especially in precarious situations during or in the aftermath of war. The 322 patients we have presented were all operated on within a short timeframe by the same surgeon; the series is unique in its representation of 20th-century warfare facial injuries and shows the predominance of shrapnel as a cause of extensive facial trauma.

Acknowledgment

The authors would like to express their sincere gratitude to the *Association Française des Chirurgiens de la Face* (AFCF), in particular Prof. Testelin and Prof. Devauchelle, for granting access to the documents and photos of the Tessier Collection (Centre Hospitalo-Universitaire d'Amiens, Université de Picardie). This research did not receive any specific grant from funding agencies in the public, commercial, or not-for-profit sectors.

References

1. Akhlaghi F, Aframian-Farnad F. Management of maxillofacial injuries in the Iran-Iraq war. *J Oral Maxillofac Surg* 1997;55:927–31.
2. Al-Shawl A. Experience in the treatment of missile injuries of the maxillofacial region in Iraq. *British Journal of Oral and Maxillofacial Surgery* 1986;24(4):244–50.
3. Ansell MJ, Breeze J, McAlister VC, Williams MD. Management of devastating ocular trauma — experience of maxillofacial surgeons deployed to a forward field hospital. *Journal of the Royal Army Medical Corps* 2010;156(2):106–9.
4. Breeze J, Gibbons AJ, Opie NJ, Monaghan A. Maxillofacial injuries in military personnel treated at the Royal Centre for Defence Medicine, June 2001 to December 2007. *Br J Oral Maxillofac Surg* 2010;48:613–6.
5. Carey ME. Analysis of wounds incurred by US Army Seventh Corps personnel treated in Corps hospitals during Operation Desert Storm, February 20 to March 10, 1991. *J Trauma* 1996;40(3 Suppl):S165–9.
6. Dobson JE, Newell MJ, Shepherd JP. Trends in maxillofacial injuries in war-time (1914–1986). *Br J Oral Maxillofac Surg* 1989, 27(6):441–50.
7. Eiseman B. Casualty care planning. *J Trauma* 1979;19(11):848–51.
8. Khosravi MH, Akhavan A. Facial injuries in Iranian veterans during the Iraq-Iran war (1980–88): differences from recent conflicts. *Br J Oral Maxillofac Surg* 2015;53(10):949–52.

9. Mader TH, Carroll RD, Slade CS, George RK, Ritchey JP, Neville SP. Ocular war injuries of the Iraqi insurgency, January–September 2004. *Ophthalmology* 2006;113(1):97–104.
10. Mertens C, Decker C, Engel M, Sander A, Hoffmann J, Freier K. Early bone resorption of free microvascular reanastomized bone grafts for mandibular reconstruction — a comparison of iliac crest and fibula grafts. *J Craniomaxillofac Surg* 2014;42:e217–223.
11. Motamedi MH, Behnia H. Experience with regional flaps in the comprehensive treatment of maxillofacial soft-tissue injuries in war victims. *J Craniomaxillofac Surg* 1999;27(4):256–65.
12. R Core Team (2016). R: a language and environment for statistical computing. R Foundation for Statistical Computing, Vienna, Austria. URL <https://www.R-project.org/>.
13. Sadda RS. Maxillofacial war injuries during the Iraq-Iran war: an analysis of 300 cases. *Int J Oral Maxillofac Surg* 2003;32(2):209–14.
14. Simon F, Ketoff S, Guichard B, Wolfe SA, Tulasne JF, Bertolus C, Khonsari RH. Lower jaw reconstruction and dental rehabilitation after war injuries: the experience of Paul Tessier in Iran in the late 1980s. *J Craniomaxillofac Surg* 2015;43(5):606–10.
15. Taher AAY. Management of weapon injuries to the craniofacial skeleton. *J Craniomaxillofac Surg* 1998;9(4):371–82.
16. Talmant JC: Use of neck muscle in the correction of facial asymmetry. The Barron-Tessier flap. *Rev Stomatol Chir Maxillofac* 1983;84:e283–288.

17. Tessier P, Matthews DC, Kamerer Jr D, Ciminello FS, Gargano F, Wolfe SA: Platysma-based myocutaneous clavicular island flap for intraoral reconstruction. *Ann Plast Surg* 2011;67:S55–69.
18. Wolfe SA. In: Wolfe SA (ed.), A man from Heric. The life and work of Paul Tessier, MD, father of craniofacial surgery, Lulu.com, London. 2012.
19. Wolfe SA. The influence of Paul Tessier on our current treatment of facial trauma, both in primary care and in the management of late sequelae. *Clin Plast Surg* 1997;24(3):515–8.

Legends

Table 1. Description of the cohort of patients operated on by Paul Tessier in Iran from 1990 to 1993.

Table 2. Results of the multivariate logistic model; OR = odds ratio

Figure 1. Preoperative and postoperative images of a 28-year-old man assessed by Tessier in Tehran in 1991; facial trauma by shell fragments in 1981. Orbital cavity repair using multiple fronto-parietal grafts.

Figure 2. (*left*) Age distribution density curve at the time of trauma — dotted line; 18 years of age. (*right*) Distribution density curve for the years of injury occurrence.

Figure 3. Distribution diagram for injury mechanism (percentages); NA = not available.

Figure 4. Anatomical distribution of craniofacial bone lesions: upper third, middle third, and lower third of the craniofacial skeleton; and soft-tissue lesions, excluding burns.

Figure 5: Distribution of the different procedures performed by Tessier and his team; TMJ = temporomandibular joint.

Figure 6: (Upper row) Bone or rib graft site distribution (percentages); OM temporal graft = osteomuscular temporal graft. (Lower row) Distribution of the bone and/or rib graft site.

Supp. Fig. 1. Age distribution of patients at assessment by Tessier.

Supp. Fig. 2. Anatomical localisation of lesions: upper, middle, and lower thirds of the craniofacial skeleton, and affected craniofacial soft tissues.


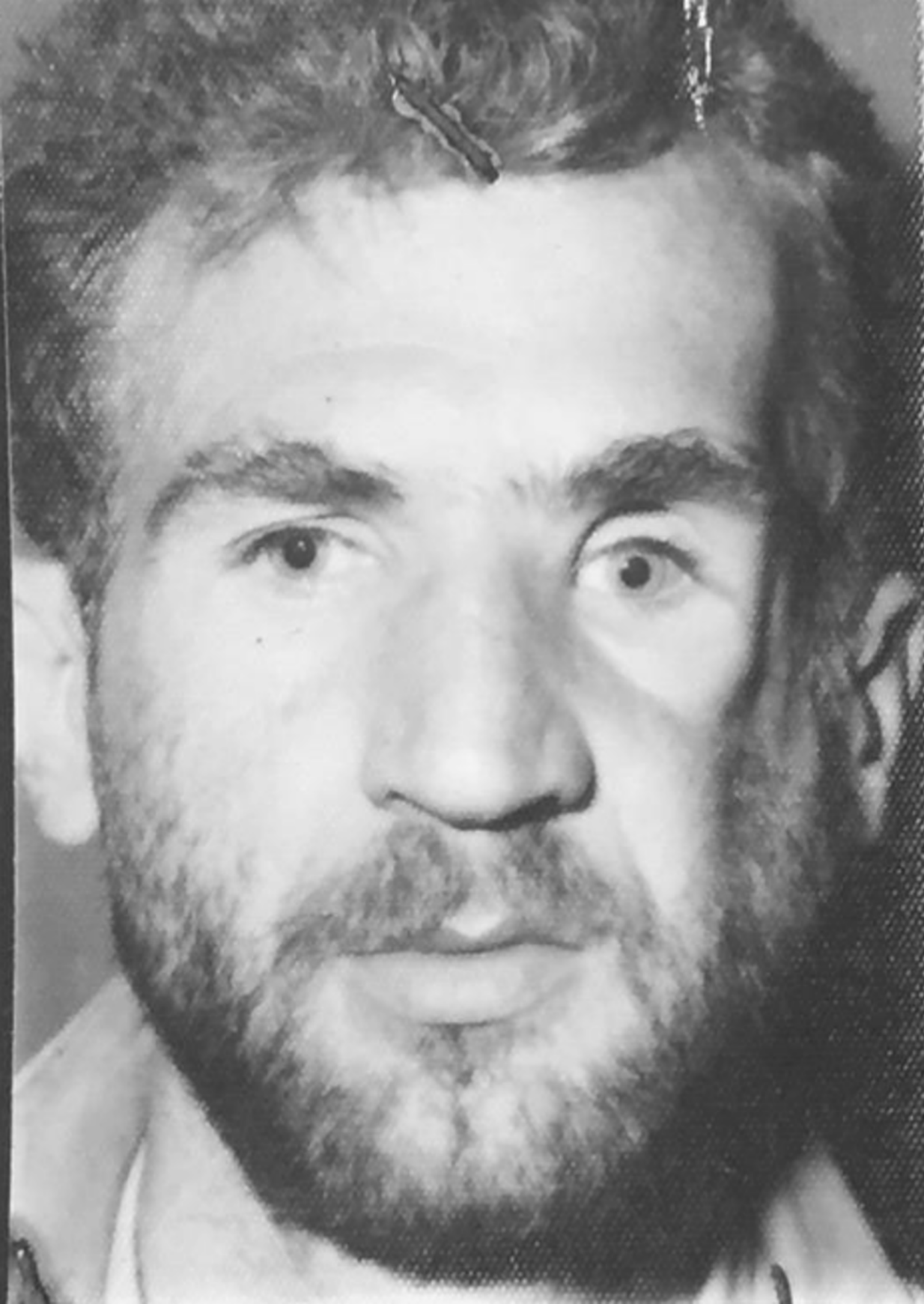
Supp. Fig. 3. (left) Distribution of the number of previous surgeries. (right) Countries in which surgeries were performed.

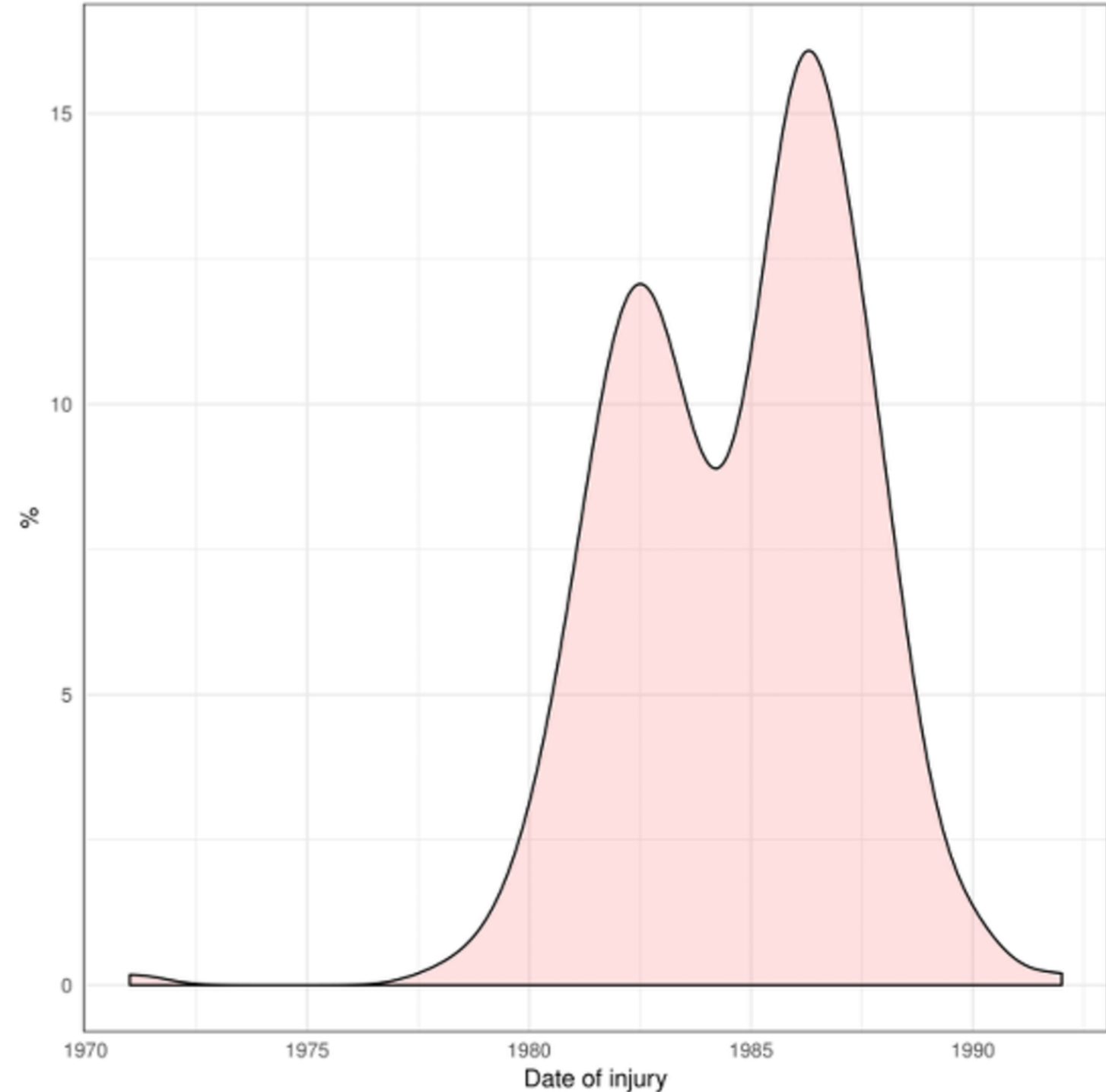
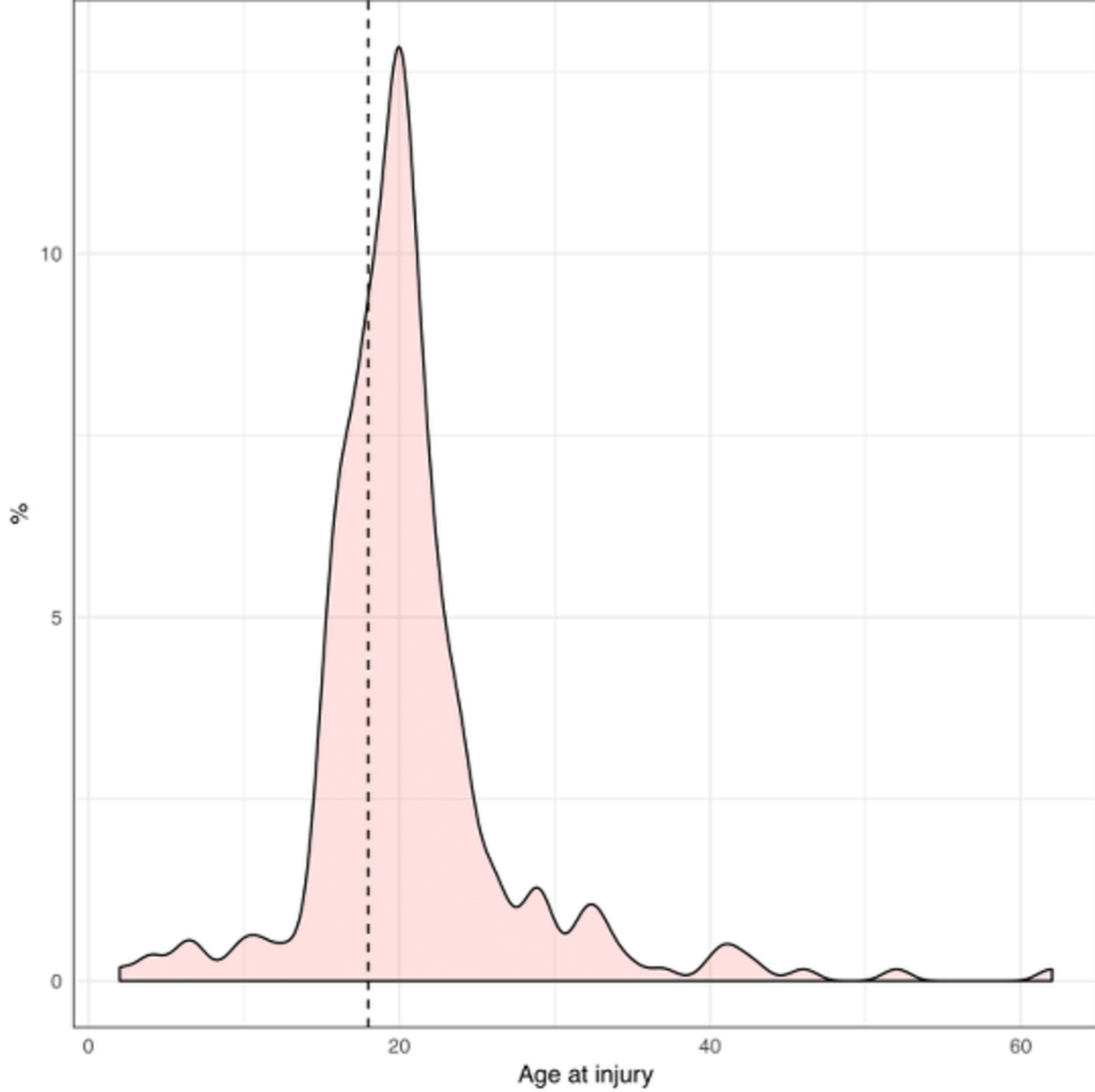
Supp. Fig. 4. From left to right: Distribution of orthognathic surgery, orbital refection surgery, and rhinoplasty techniques.

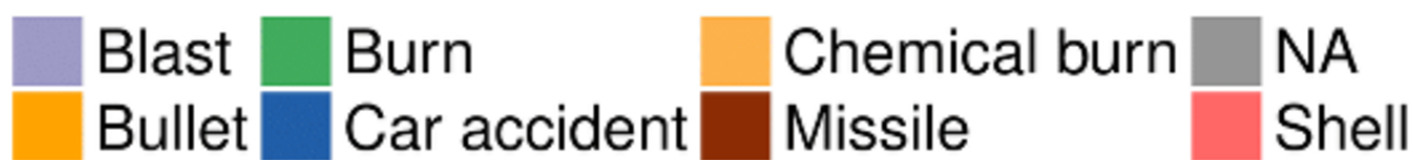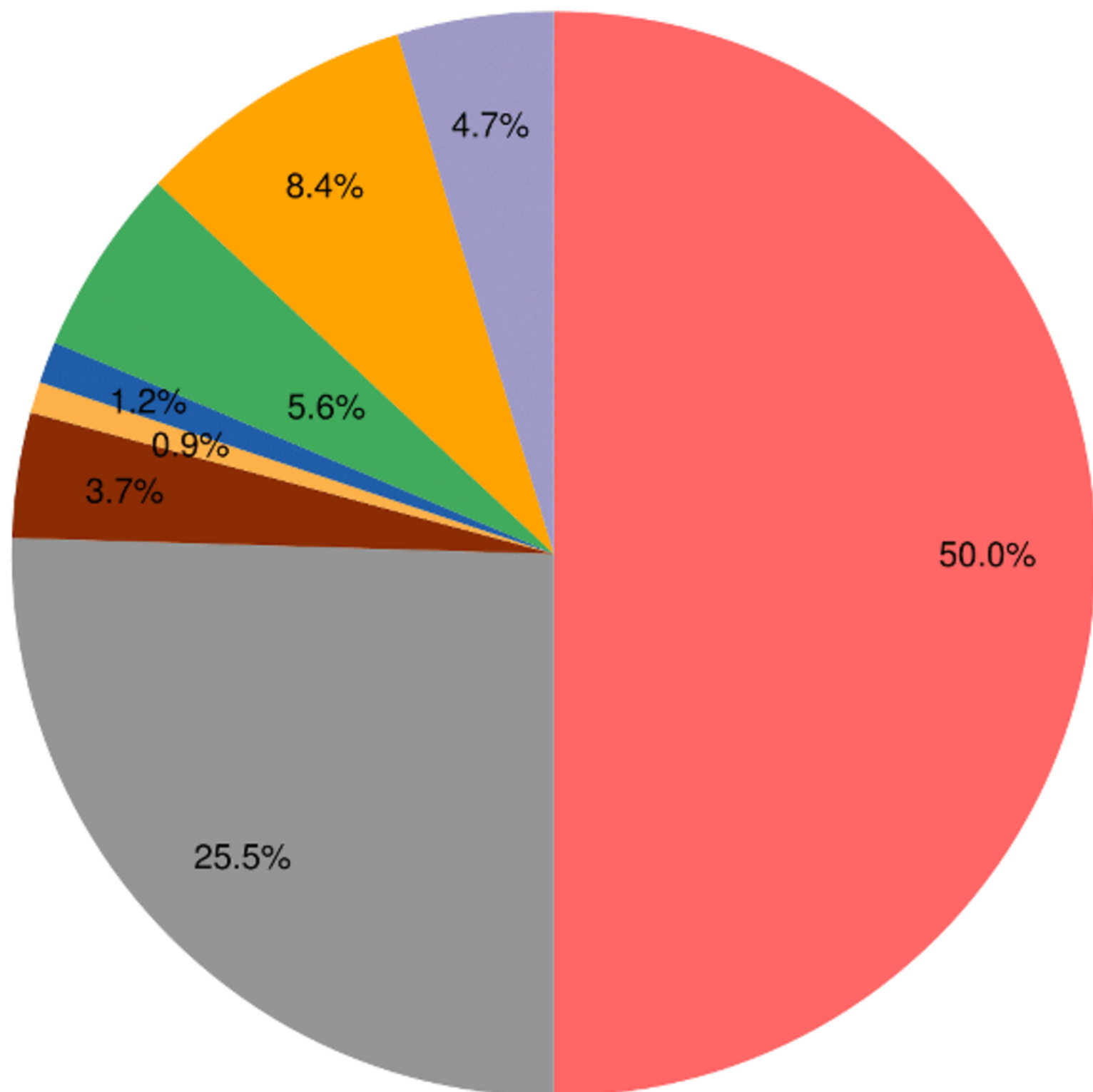
Supp. Fig. 5. Different pedicled or free flaps performed by Tessier.

Supp. Fig. 6. Distribution of complications observed in the files.

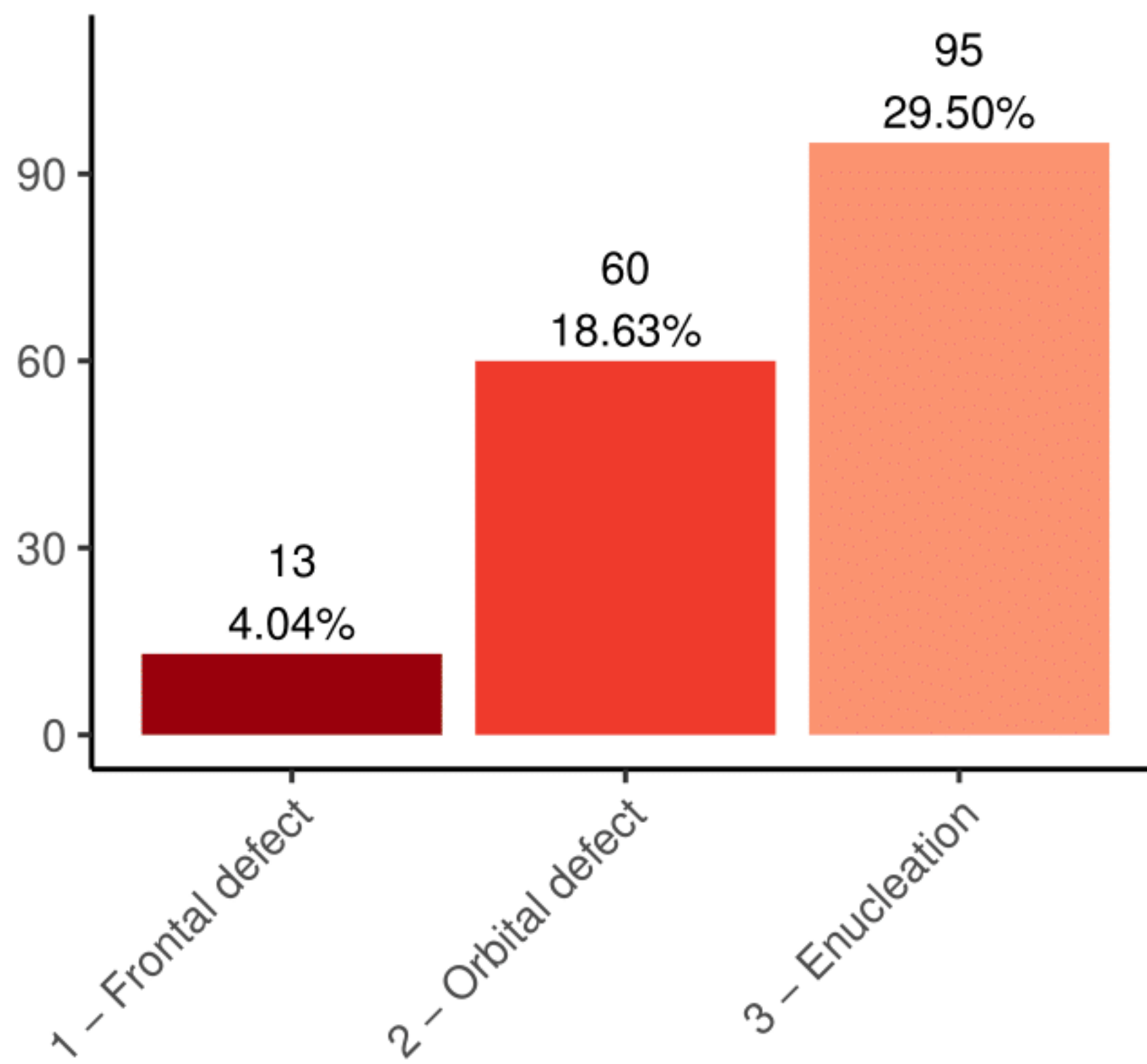
Supp. Fig. 7. Odds ratio value, with its confidence interval, for shell fragment, extracted from the multivariate logistic model for enucleation risk. The asterisk indicates a significant result, i.e. a confidence interval that does not include the value 1.



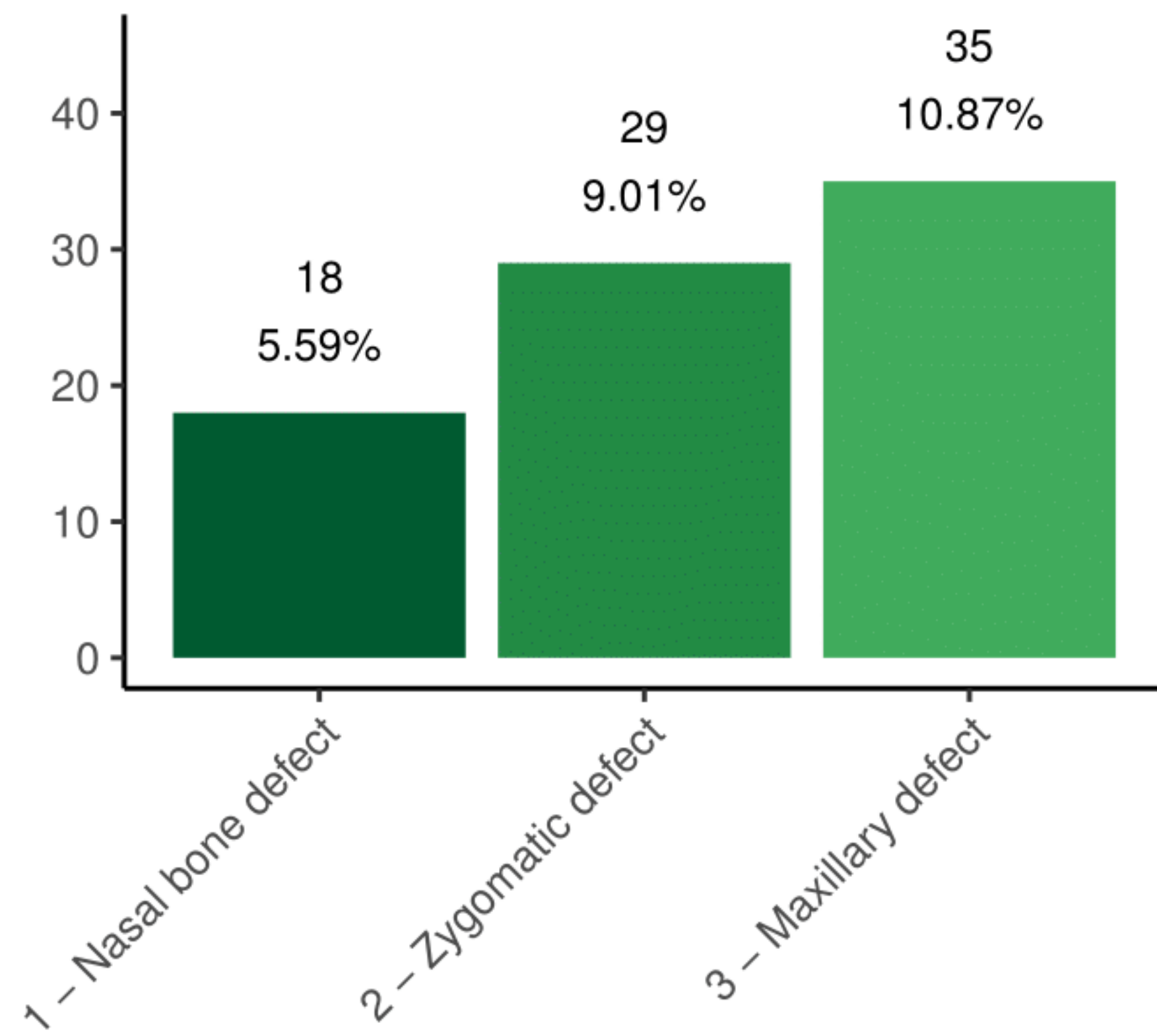




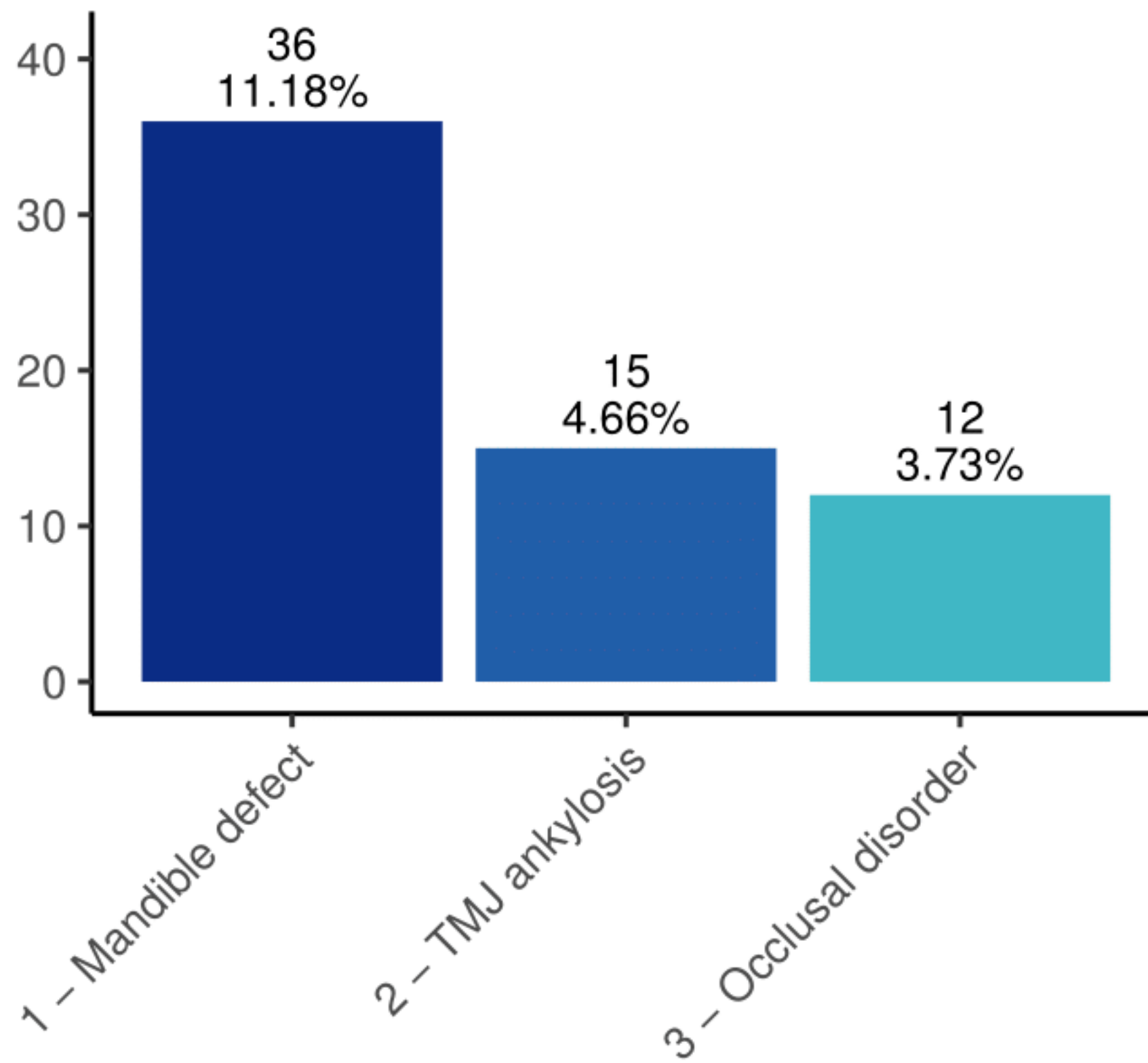
Craniofacial injuries : upper third



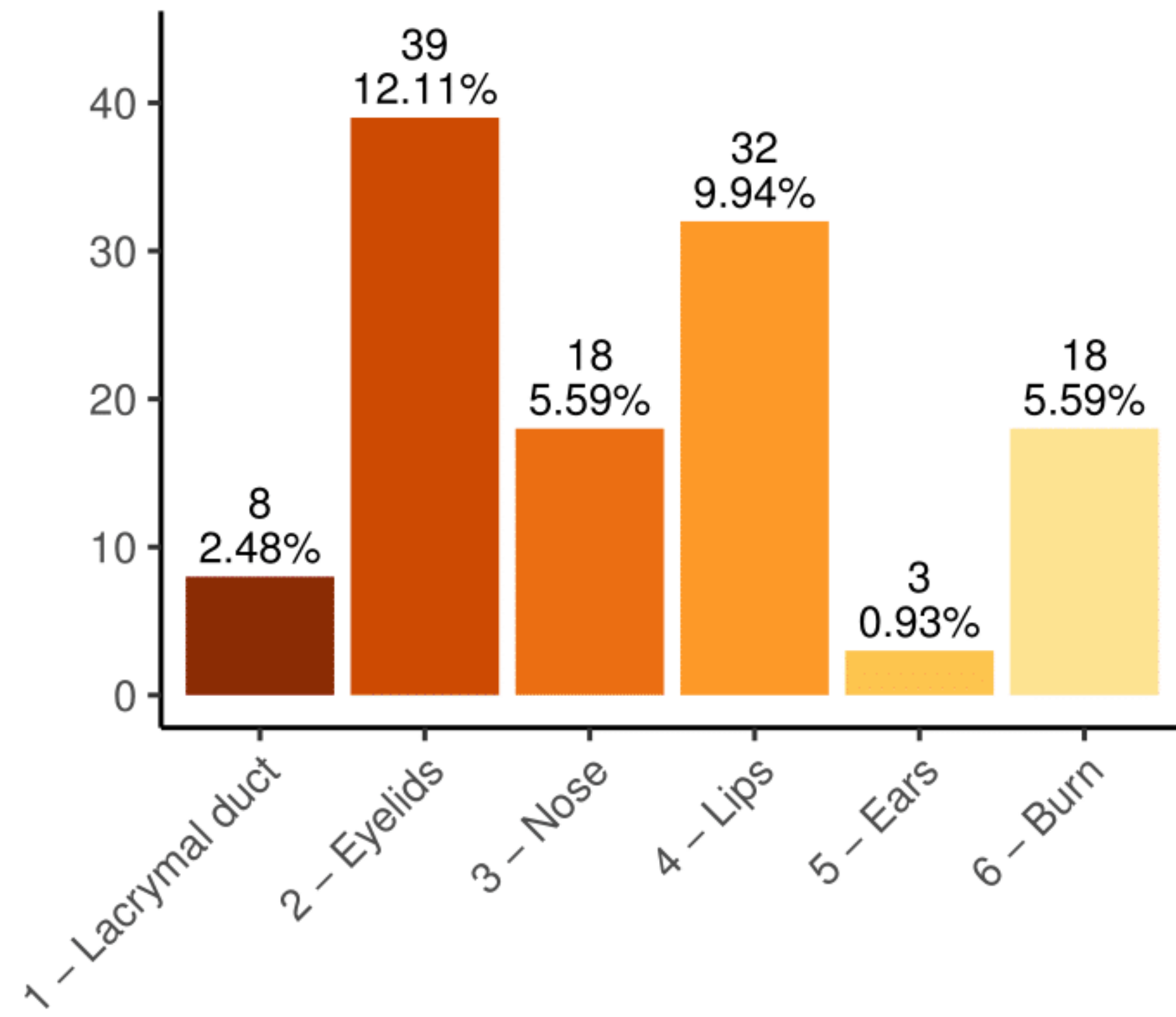
Craniofacial injuries : middle third



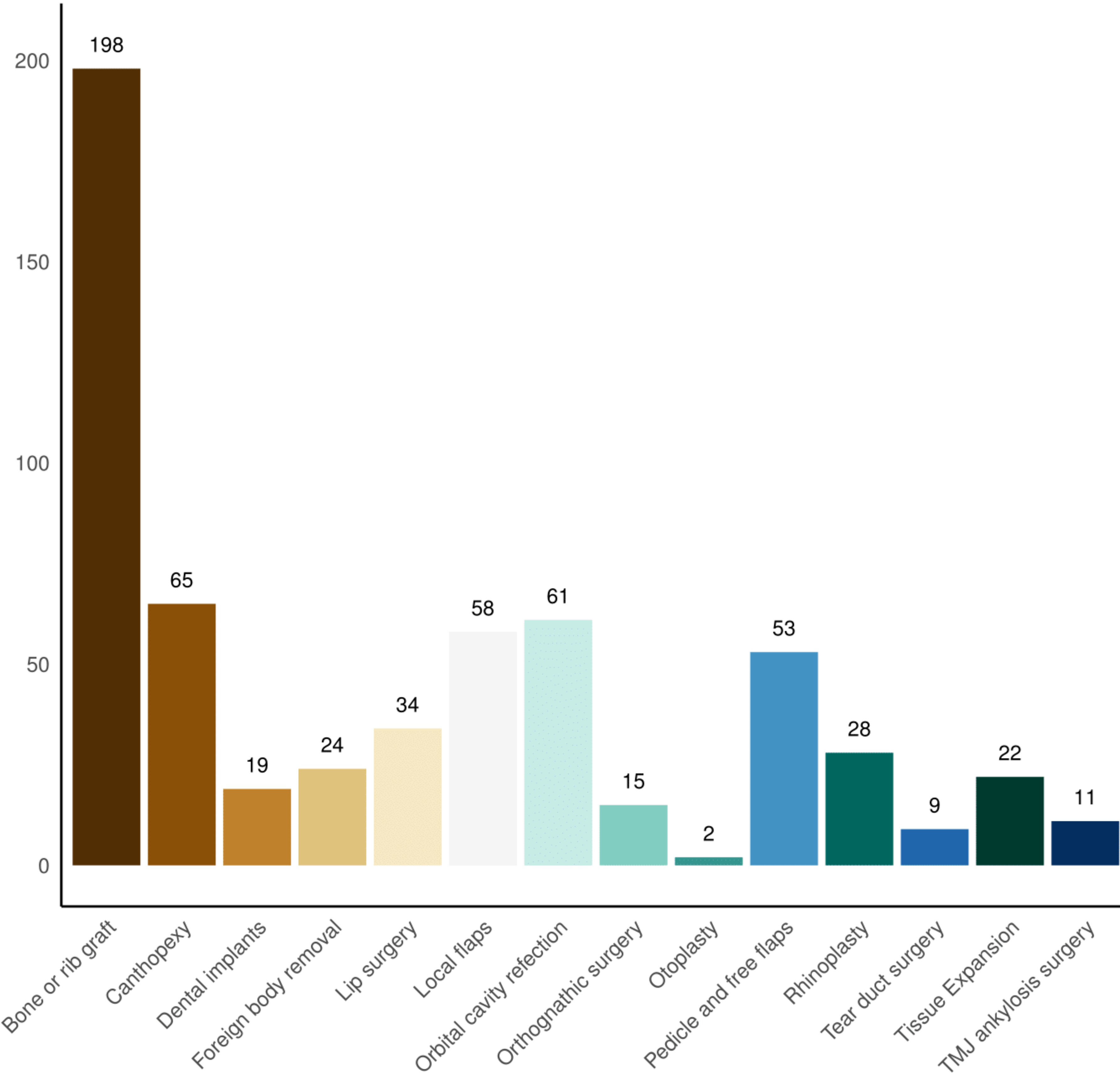
Craniofacial injuries : lower third

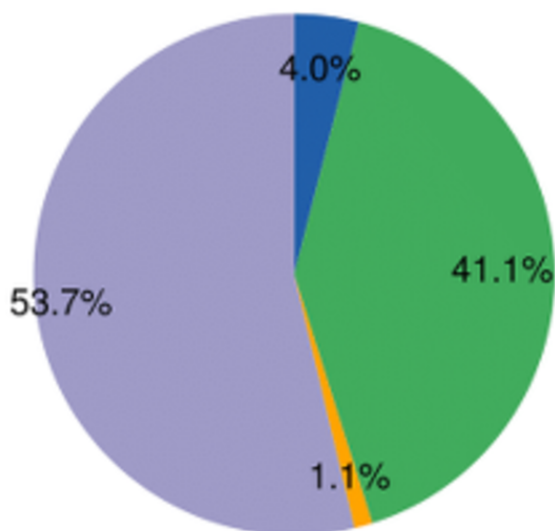


Soft tissues injuries

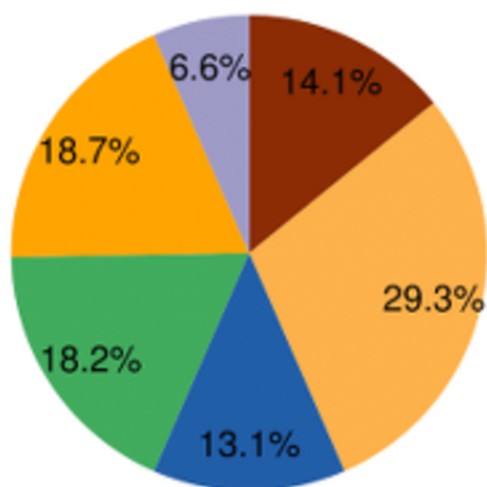


Performed surgeries





Calvarial
 Costal
 Iliac
 OM temporal



Frontal bone
 Maxilla
 Orbit
 Mandible
 Nasal crest
 Zygoma

Table 1. Description of the cohort of patients operated on by Paul Tessier in Iran from 1990 to 1993.

	<i>N</i>	Min.	Max.	Mean (\pm SD)/frequency
Consultation date	322	1990	1993	
Gender	322			322
Male	305			94.72%
Female	17			5.28%
Age	308	5	67	27.15 \pm 6.97
Age at injury	280	2	62	20.65 \pm 7.04
Date of injury	287	1971	1992	
Under 18 years old	280			21.12%
Injury mechanism	240			
Blast	15			4.66%
Bullet	27			8.38%
Missile	12			3.73%
Shell	161			50.00%
Burn	18			5.59%
Chemical burn	3			0.93%
Car accident	4			1.24%
Previous surgeries	211	0	40	6.22 \pm 7.25
Flaps	28			
Grafts	46			
Upper face	124			38.50%
Frontal bone defect	13			4.04%
Orbital defect	60			18.63%
Enucleation	95			29.50%
Mid face	72			22.36%
Nasal bone defect	18			5.59%
Zygomatic defect	29			9.01%

Maxillary defect	35	10.87%
Lower face	86	26.71%
Mandible defect	36	11.18%
TMJ ankylosis	15	4.66%
Occlusion	12	3.73%
Plastic	136	42.24%
Tear duct	8	2.48%
Eyelids	39	12.11%
Nose	18	5.59%
Lips	32	9.94%
Ears	3	0.93%
Burn	18	5.59%
<hr/>		
Harvesting	175	
Iliac bone	72	41.14%
Fronto and/or parietal bone	94	53.71%
OM temporal	7	4.00%
Rib	2	1.14%
Graft site	198	
Frontal	13	6.57%
Orbit	58	29.29%
Nose	26	13.13%
Zygoma	28	14.14%
Maxillary	36	18.18%
Mandible	37	18.69%
<hr/>		
Surgeries performed	322	
Bone or rib graft	198	61.49%
Foreign body removal	24	7.45%
Dental implants	19	5.90%
Orthognathic surgery	15	4.66%

TMJ ankylosis surgery	11	3.42%
Canthopexy	65	20.19%
Lip surgery	34	10.56%
Orbital cavity refection	61	18.94%
Local flap	58	18.01%
Rhinoplasty	28	8.70%
Expansion surgery	22	6.83%
Tear duct surgery	9	2.80%
Otoplasty	2	0.62%
Pedicle and free flap	53	16.46%
Orthognathic surgery	15	
Le Fort I osteotomy	4	26.67%
Sagittal split	2	13.33%
Genioplasty	9	60.00%
Vestibuloplasty	28	
Epithelial inlay	6	21.43%
Thiersch graft	10	35.71%
Orbital cavity refection	61	
Epithelial inlay	20	32.79%
Full thickness skin graft	27	44.26%
Conformer	31	50.82%
Pseudorraphy	47	77.05%
Rhinoplasty	28	
Bone graft	26	92.86%
Septoplasty	14	50.00%
Conchal graft	11	39.29%
Pedicle of free flaps	53	
Temporal	22	41.51%
Abbé	5	9.43%

Baron-Tessier	7	13.21%
Scalp	14	26.42%
Free flap	3	5.66%
Other	2	3.77%
<hr/>		
Complications	25	7.76%
Infection	21	6.52%
Pseudarthrosis	4	1.24%
Graft necrosis	5	1.55%
Bleeding	1	0.31%
Others	2	0.62%
<hr/>		
CT-scan	54	16.77%
3D reconstruction	10	3.11%

Table 2. Results of the multivariate logistic model; OR = odds ratio.

	OR	2.5%	97.5%	<i>p</i>
Female	0.781	0.045	2.401	0.789
Age	0.964	0.905	1.017	0.211
Shell	4.039	1.325	17.599	0.029