



**HAL**  
open science

## Chapter 8 Memory dysfunctions

Pascale Piolino, Christine Bulteau, Isabelle Jambaqué

► **To cite this version:**

Pascale Piolino, Christine Bulteau, Isabelle Jambaqué. Chapter 8 Memory dysfunctions. Handbook of Clinical Neurology, 174, Elsevier, pp.93-110, 2020, Handbook of Clinical Neurology, 10.1016/B978-0-444-64148-9.00008-9 . hal-04025189

**HAL Id: hal-04025189**

**<https://u-paris.hal.science/hal-04025189v1>**

Submitted on 11 Mar 2023

**HAL** is a multi-disciplinary open access archive for the deposit and dissemination of scientific research documents, whether they are published or not. The documents may come from teaching and research institutions in France or abroad, or from public or private research centers.

L'archive ouverte pluridisciplinaire **HAL**, est destinée au dépôt et à la diffusion de documents scientifiques de niveau recherche, publiés ou non, émanant des établissements d'enseignement et de recherche français ou étrangers, des laboratoires publics ou privés.

# Memory Dysfunction

Pascale Piolino<sup>1,2</sup>, Christine Bulteau<sup>1,3</sup>, Isabelle Jambaqué<sup>1</sup>

University of Paris, MC<sup>2</sup>Lab, Institute of Psychology, F-92100 Boulogne-Billancourt, France

Institut Universitaire de France (IUF), Paris, France

Department of Pediatric Neurosurgery, Rothschild Foundation Hospital, 75019 Paris, France

## Abstract

Since the seminal work on the patient HM, who presented in his adulthood an acquired amnesic syndrome following the resection of the bilateral temporal lobe, some other research described several cases of isolated memory dysfunctions in children. This chapter aims to present developmental and long-lasting memory disorders, emerging from an organic or neurological cause at birth or in infancy. More notably, we will focus on developmental amnesic syndrome causes by neonatal bi-hippocampal damages, and memory dysfunctions caused by medial temporal developmental epilepsy. We will describe these two pediatric populations and will present the consequences of hippocampal/medial temporal lobe damage in the development of memory systems. We will review episodic memory deficits in children with developmental amnesia and temporal lobe epilepsy and highlight their impact on new learnings, personal memories, and independent life. Finally, we will provide a brief overview of some of the insights and debates emerging from classic work and recent advances in the context of episodic memory dysfunction displayed by children with hippocampal/medial temporal lobe amnesia and will propose new perspectives in child neuropsychology of memory suggesting new avenues for more ecological memory assessment and rehabilitation.

**Keywords.** Amnesic syndrome, developmental amnesia, temporal lobe epilepsy, hippocampus, episodic memory, autobiographical memory, retrograde amnesia, anterograde amnesia.

## **Introduction**

Understanding amnesia as a profound loss of memory has been substantially driven by case studies first in adults and more recently in infants. Memory dysfunction is labeled as pure amnesia when there is an isolated alteration of long-term or declarative memory in the context of the preservation of intelligence and other cognitive functions. The 'amnesic syndrome' has been described from a vast majority of single cases representing permanent adult-acquired memory loss, such as the famous epileptic adult patient HM, who underwent a bi-hippocampectomy in 1953 (Scoville & Milner, 1957). In adults, the neural basis of amnesia depends on the etiology and extent of lesions, but more commonly is associated with damage to the medial temporal lobes (MTLs), and to the hippocampus more specifically. These amnesic syndromes contributed to understanding the role of the hippocampus and, more broadly, of the medial temporal lobe (MTL) in memory functions. They have been of significant insight to disentangle memory systems, especially the distinctions within long-term declarative memory systems between episodic and semantic memory. Indeed, memory dysfunctions in pure amnesia concern a specific type of declarative memory, which is episodic memory.

The concept of episodic memory has been proposed for the first time in 1972 by Tulving to designate a memory system that encodes, and stores information related to specific personal events located in a spatial and temporal context (Tulving, 1983). This system is opposed to semantic memory that stores general knowledge without contextual reference (see Chapter Memory Development). Since then, Tulving's work has evolved the concept of episodic memory and its relationships with other memory systems. It depends on the semantic memory system but goes beyond (Tulving, 1985, 2002). Thus, nowadays, episodic memory is viewed as a unique neurocognitive system associated with various characteristics, such as feature binding, self-reference, subjective sense of remembering, and mental time travel into the past. So perhaps the most debated issue this last decade is that of the role of MTL structures in the episodic memory (recollection of specific memories in context) and semantic memory (familiarity and expression of knowledge).

Today, even if episodic memory problems in children have generated less research than in adult patients, amnesic syndromes have been reported in children in connection with various pathologies affecting the internal structures of the temporal lobe and more or less complicated by the occurrence of epilepsy or in the context of surgery for temporal lobe epilepsy (Broman et al., 1997; Brizzolara et al., 2003; Martins et al., 2006). Back to the origins in 1997, Vargha-Khadem et her colleagues describe, for the first time, a new form of the amnesic syndrome, no longer resulting from lesions acquired in adults like the famous case HM, but emanating from early bi-hippocampal damage during the first years of life.

## **Memory dysfunction in developmental syndrome amnesia**

### **Developmental syndrome amnesia**

Developmental amnesia (DA) is a pure episodic memory disorder associated with selective bi-hippocampal damage resulting from hypoxic/ischemic episodes that occur perinatally or early in childhood. Typically, developmental amnesia occurs when the bilateral reduction in hippocampal volume is at least 20 to 30% (Isaac et al., 2013). DA, therefore, represents a study model for the dissociation between episodic and semantic memory and confirms the critical role of hippocampal regions in the constitution of episodic memories. However, the degree of atrophy can be determinant for the extent of memory disorder (Patai et al., 2015). Beyond the MTL, some studies suggest that other structures can be damaged and play an indirect role in the occurrence of memory disorders in DA, especially the diencephalic regions (Rosenbaum et al., 2014). Interestingly, DA makes

it possible to investigate developmental memory deficits selectively and to shed light on the neural reorganization of the memory network due to early-life damage. All in all, while episodic memory deficits are devastating for the autonomy of these patients, this syndrome has been the subject of relatively few scientific descriptions.

In the late 1990s, Vargha-Khadem and her colleagues (1997, 2001) were the first to identify developmental syndrome amnesia in adolescents or young adults for whom medical history has evoked the existence of early bi-hippocampal injury. They described the case of three young patients, Jon, Beth, and Kate, suffering from striking deficits of memory function caused by neonatal lesions (episode of hypoxia-ischemia (lack of oxygen) for Jon and Beth, combined with seizures on the third day of life for Beth, or injury during childhood by intoxication for Kate). All three patients with early-onset, or developmental amnesia, had massive bi-hippocampal atrophy identified as the critical factor of the onset of developmental amnesia. The volume of the bilateral hippocampus was under 50% of that of healthy children. Their amnesic condition was a permanent disorder, emerging from a neonatal to infancy cause, that dramatically concerned the memory for events grounded in time and space. All these difficulties were reported by parents and educators emphasizing particularities of memory functioning from the school-age, but also, objectified in the neuropsychological tests. However, they seemed to have preserved learning skills since they presented regular schooling.

These DA patients showed average intelligence, intact language, and motor and procedural memory abilities, but minimal long-term memory following short periods of interference (about a few minutes), alongside relatively intact short-term and working memory. Above all, they seemed particularly deficient in delayed recall, whatever the material, with relative preservation of recognition skills. However, they could recognize new information based on familiarity. For instance, formal testing of Jon's memory revealed impairments on standard tests of episodic memory (learning and recall of lists of items), but the preservation of semantic knowledge (Vargha-Khadem et al., 1997; 2001). However, while Jon's recall scores are consistently and significantly below those of matched controls (Vargha-Khadem et al., 1997; Baddeley et al., 2001; Brandt et al., 2006), he tends to demonstrate normal levels of performance on many tests of recognition for both verbal and non-verbal material (Vargha-Khadem et al., 1997; Baddeley et al., 2001; Gardiner et al., 2006). Yet, a re-examination of the recognition memory of Jon using test procedures that provide assessments of the separate contributions to the recognition of recollection and familiarity reveals that Jon bases his recognition on familiarity, not on recollection. Since then, several studies (Baddeley et al., 2001; Gardiner et al., 2006), which used the Remember/Know paradigm (Tulving, 1985), found that asking patient Jon to make recognition-based judgments regarding whether he recognizes an item either because he remembers (R) encountering this item earlier or simply know (K), showed that correct recognition was not related to the recollection of source of information. Gardiner et al. (2006) showed that whereas matched controls correctly differentiated between remembering and knowing based on contextual details, Jon did not and, instead, distinguished between the two types of responses based on the confidence level. Of interest, the finding of an event-related potential (ERP) study with Jon found the ERP signature related to familiarity based recognition (N400 time window) but not the one linked with recollection (late positive component, 500–700 ms) (Düzel et al., 2001). This dissociation was also corroborated (Gardiner et al., 2008) by employing another procedure to differentiate familiarity and recollection (the Process Dissociation Procedure, PDP; Jacoby, 1991).

Since the three cases by Vargha-Khadem, especially Jon's case, other patients with early-onset amnesia have been described in detail as well as some follow up studies from childhood to adulthood. Interestingly, one study of 40 children presenting acute respiratory failure at birth (neonatal hypoxia), but without apparent brain damage, revealed that early hippocampal volumes were predictive of the degree of memory impairment later in life (Cooper et al., 2006). Also, the reduction in hippocampal volume (including Amon's horn, dentate gyrus, subiculum, and pre-subiculum and uncus) correlates strongly with recall performance while recognition performance,

much closer to those of controls, appears unrelated with the hippocampal volume. Moreover, the occurrence of epilepsy can complicate DA (Martins et al., 2006). In this case, there can be a more severe cognitive impairment than in Vargha-Khadem's patients.

## **The consequences of the early-onset amnesic syndrome**

### ***Learning and encoding processes***

The episodic memory deficit in DA is not without consequences in new learning and the nature of knowledge. When asking Jon, then aged 25 years old, to acquire cultural information about the world, he needs much time to learn and much more practice for memorizing only half of the information in comparison with a group of participants from the same age (Gardiner et al., 2008). Thus, a slowdown in learning combined with forgetting learning context and massive repetitions is usual in AD.

Remarkably, patients with DA can learn new information at school, but differently than typically developing individuals. The difference is due to strategies used for learning and the nature of knowledge acquired. Given the fact that episodic memory is a late-developing memory system whose emergence comes at 4 years old (Tulving, 1985), the atypical memory function of DA children may remain long ignored by the parents until the entry to the school. Moreover, in the presence of ordinary schooling, although the learning is often the result of intensive work, DA diagnosis can be delayed until late childhood or adolescence. The testimony of parents of DA patients is very insightful of deliberate or more procedural strategies to improve their learning and capacity to answer questions about their recent and more remote personal experiences. Parents frequently report an overdevelopment of domains of competency in memory (e.g., visual, or cultural knowledge), or optimization of their use as a compensation process. Being aware of her memory problems, Valentine (box 1) presented an excellent capacity for learning via semantic methods (multiple repetitions via several reports and readings, reasoning, and inference based on the activation of semantic networks). She appeared to be much more cultivated than people of her age with a great deal of detailed and sophisticated knowledge of the history of ancient Greece in particular.

The neuropsychological profile of the DA patients, capable of semantic acquisitions (e.g., naming test, information subtest from Wechsler Intelligence Scale for Children), despite deficits in episodic memory (e.g., Children Memory Scale), confirms naturalistic observations, and thus provides a strong argument in favor of the distinction between episodic and semantic long-term memory systems based on separate brain areas. Therefore, the remarkable conservation of familiarity and recognition skills constitutes a key feature of AD patients. They present not only excellent recognition memory for material presented several times, but also sometimes shown only one time, and this despite severe episodic amnesia (e.g., Picard et al., 2014; Jonin et al., 2018). Nevertheless, learning in DA concerns items and not their context suggesting either the contribution of a set of implicit or nondeclarative memory systems in learning (e.g., automatic, priming, procedural) or that of some explicit or declarative memory processes based on semantic memory. Indeed, they have relatively preserved factual knowledge, thus the capacity to acquire and store semantic memory.

In contrast, learning of new contextual or spatial information is dramatically impaired. Thus, DA patients are very easily disorientated and need a very long time to learn a route or space. Some recent case studies examined in more details learning deficits in DA by employing what-where-when memory tests (e.g., the association between object, place, and temporal information). These tests are closer to the complexity of episodic memory in real-life situations and are very sensitive to hippocampal binding functions (Sander et al., 2012). While patients can recall some items in standard learning tests of episodic memory (e.g. 15 word Rey test), their performance collapsed when the

tests required the memorization of associated information, that is feature binding (Picard et al., 2014; Olsen et al., 2015). We illustrated this associative memory deficit with Valentine's case (see Box 1, Figure 1).

### ***Knowing without remembering our life***

Being able to recall the past but also imagine the future are prerequisites for independent living. Living in a permanent present has many consequences not only for independent living but also for the construction of personal identity. On the one hand, the memory of remote personal events in DA is vague as well as the memory of recent events such as a conversation or the last family outing. Compared to the acquired-amnesic syndrome in adults, autobiographical memory, and the ability to imagine future scenarios is relatively unexplored in early-onset amnesia, despite the importance of these functions for development of personal identity (Abram et al., 2014). Even if the patient Jon presented with impaired autobiographical memories, he was able to recall some personal information. This profile corroborates that autobiographical memory involves the recall of personal information (semantic autobiographical memory), and re-experiencing of specific personal events (episodic autobiographical memory), which are respectively preserved and impaired in amnesia syndrome (Tulving et al., 2001, 2002; Piolino et al., 2009). Jon was included in an fMRI study investigating the neural correlates of recognition of sentences describing personal events from his past based on a previous questionnaire (Maguire et al., 2001). The results showed a pattern of brain activations like control subjects in the medial and lateral left areas of the brain. In addition, some increased activations in homologous areas in the right hemisphere were observed. Of interest, despite the 50% volume loss in bilateral hippocampus, autobiographical memory retrieval was associated with bilateral activity of the hippocampus. Moreover, like controls, hippocampal activity reaches a higher level for autobiographical events compared to other types of information more semantic in nature (autobiographical facts, public events, general knowledge), but unlike controls, Jon did not present increased effective hippocampal-cortical connectivity. Overall, the findings suggest that the residual hippocampal tissue can contribute to the retrieval of the few preserved autobiographical memories. Nevertheless, using sophisticated tests (e.g., TEMPau, Piolino et al., 2009), other studies showed that episodic autobiographical memory is dramatically altered in DA (see case Valentine, Box 1, Figure 2). In a group study comparing 21 children who had experienced neonatal hypoxia/ischaemia, and consequent bilateral hippocampal damage, with a group of healthy school-aged children, the results showed that patients could not recall autobiographical events with spatiotemporal information and specific episodic details (Cooper et al., 2011). First, it demonstrates that patients with early-onset amnesia may ground autobiographical memory from an early age, but it consists of personal semantics. Children or adults with a history of DA know their past from a general point of view (e.g., their habits, the names of friends and family members, addresses...), but they don't remember specific instances (a birthday, the last Christmas, the visit at the museum). They based their 'pseudo' memories on familiarity and guessing neither on "re-experiencing" the past. Thus, they can recall personal events based on semantic information, while they are incapable of evoking phenomenological details (perceptions, feelings, thoughts). Their personal life history seems vague, impoverished, and fossilized.

The case Valentine (Picard et al., 2014) knows her identity (i.e., the conceptual self that is composed of beliefs, attitudes, values of the individual and her personality traits), but this self-knowledge is frozen in time, based on the view of her parents on herself rather than an experience of herself. Similarly, Valentine, like other DA patients, cannot imagine specific instances in their future. Thus, they are unable to travel mentally in time, either in their past or their future (Kwan et al., 2010). Like adult-acquired-amnesic syndrome, DA patients describe both temporalities as a blankness (Tulving et al., 2001, 2002). Remarkably, this alteration is independent of deficits in imagination skills or construction of fictitious scenarios (Cooper et al., 2011; Hurley et al., 2011). In this line, Jon showed preservation in constructing scenes in his imagination during an fMRI study which suggest preserved capacity in projecting into the future (e.g., imagine standing on a crowded platform of a train station)

(Mullally et al., 2014). He activated the same brain regions as controls (including ventromedial prefrontal cortex, posterior cingulate, retrosplenial and posterior parietal cortices), except for the hippocampal region. Thus, it suggests that the imagination of future scenarios results in semantic memory in line with the semantic scaffolding hypothesis of future thinking (Irish & Piguet, 2013). Despite episodic future thinking deficits in DA, intact semantic memory could support scene construction

Last but not least, when examining the nature of the sense of self when growing up without the possibility to re-experience specific personal events from an early age or pre-experience future instances, the results indicate that DA patients have ground own identity as they can answer on the question “who they are?”. These results highlight the fact that the construction of the self can be done independently of the integrity of the episodic memory system, based on semantic ones (personal habits, repeated personal events). However, their sense of self is relatively petrified compare to healthy controls. Valentine’s case (Picard et al., 2014) was able to describe herself in a very caricatural way, similarly in the past, the present and the future, her self-knowledge was mainly modeled on the image of her having their parents. She was not able to evoke episodes illustrating the characteristics of her personality traits, and consequently, she has unable to consider the expression of her personality behavior according to changing contexts. In brief, the conservation of personal semantics allows a relative sense of self and autonomy in the context of routine life.

### ***From clinical observations of DA to theoretical considerations***

In the context of the developmental amnesic syndrome, neonatal lesion damage has been dominant for the identification of isolated episodic memory deficits. Hence, the description of DA patients plays a crucial role in the debate regarding the long-term memory dissociations in amnesic syndrome and what it reveals about the function of MTL areas. Indeed, DA adds a convincing argument that episodic memory (associative, relational) depends on the integrity of the hippocampus, while that of semantic memory (schematic, decontextualized) is based on the integrity of adjacent cortices, presumably relatively preserved in these patients (perirhinal and entorhinal), (Jonin et al., 2018; see box 1, Table 1). The data also suggest that recollection is more dependent on the hippocampal formation than is familiarity, consistent with the view that the hippocampal formation plays a unique role in episodic memory, for which recollection is so critical. Therefore, the dissociation observed in DA patients brings elements, against an unitary model of declarative memory (Squire & Zola, 1996; Squire, 2004), in favor of the models that consider declarative memory divided into two different subcomponents that are underpinned by distinct structures within the MTL (e.g., SPI model of Tulving, 1985). From a developmental perspective, it argues in favor of the view that semantic memory develops before episodic memory (Tulving, 1985), in other words, that general/abstract representation does not derive uniquely from the semanticization of episodic memory (Conway, 2009; see Picard et al., 2014 for a detailed discussion).

## **Memory dysfunction in temporal lobe epilepsy in children**

### **Temporal lobe Epilepsy**

The early-onset amnesic syndrome remains relatively rare compared to the incidence of epilepsy in children. Indeed, epilepsy is the most common chronic neurological disease in children. Epilepsy is expressed by the clinical manifestation of excessive hypersynchronous neural discharge from a large part of the brain, accompanied or not by loss of consciousness. Among lobar epilepsies, temporal

lobe epilepsy (TLE) is the most common and best known, with medial temporal seizures originating in the hippocampus, the amygdala, and the hippocampal gyrus.

TLE is less common in children than in adolescents and adults and is expressed somewhat differently in children and adults (Fogarasi et al., 2007). Generally, it begins in older children who have often previously presented a history of febrile convulsions. However, TLE may be overlooked and underestimated in younger children because the recognition of complex partial seizures can be difficult before the age of 4 or 5 years. Besides, young patients are often addressed to a specialized service only when temporal epilepsy proves refractory to several anti-epileptic drugs. Early and adequate diagnostic evaluation, including an adapted neuropsychological exploration, is therefore essential to avoid complications on the epileptological level as well as on the cognitive level (Jambaqué et al. 2013).

TLE is said to be symptomatic when it is part of a neurological history (tumor epilepsy, for example) or when it can be associated with a lesion recognized by radiology thanks to MRI. First, it may be related to atrophy of the hippocampus, which develops progressively with the repetition of the temporal lobe crises associated with the death of neurons in the most vulnerable parts of the hippocampus. However, hippocampal sclerosis is also often linked to the occurrence of febrile seizures in the first years of life. The risk of developing medial-temporal epilepsy appears indeed related to febrile convulsions known as complicated and prolonged. Today, the existence of primary medial-temporal sclerosis, for instance in connection with neonatal hypoxia, is therefore recognized as being able to be the cause of temporal lobe epilepsy in children, even if this cause still seems to be underestimated (Zix et al., 1999; Gadian et al., 2000). It is also possible that hippocampal sclerosis is the consequence of a double event, namely the existence of an initially discreet and mute anomaly of the medial temporal lobe, and then hyperpyrexia (very high fever of over 41.5°C) which would initiate the first crisis. A child could, therefore, have a febrile convulsion because he already has damage to the internal temporal lobe in connection with a pre or perinatal problem combined or not with a genetic predisposition. However, it is difficult to identify these children before they have medical issues (Robain, 1998). The recent development of surgery and morphological data from MRI has made it possible to highlight abnormalities in cortical development as a significant cause of refractory epilepsy in children. Thus, many children with TLE present a double pathology associating hippocampal sclerosis and

The therapeutic objective is first to try to reduce the frequency of seizures by prescribing anti-epileptic drugs. Thanks to advances in the pharmacological field, it is now possible to offer a wide range of molecules capable of treating " the epileptic crisis symptom ". However, certain drugs - in particular, phenobarbital and the antiepileptic benzodiazepines - are likely to be associated with some intellectual retardation or in a more specific way to contribute to the impairment of memory function. TLE can thus fluctuate with the effectiveness of anti-epileptic treatment. Besides, some patients develop so-called drug-resistant epilepsy, which may lead to considering surgical treatment. Surgery for TLE represents, in fact, one of the most frequent indications for neurosurgery of epilepsy and has developed considerably in children over the past twenty years with a curative effect in 90 % of cases (Clusmann et al., 2004). TLE surgery most often involves an amygdalo-hippocampectomy and resection of the anterior part of the temporal pole. TLE surgery may also be indicated in children who have low-grade tumors, which may be accompanied by hippocampal sclerosis.

### **Memory dysfunction in TLE in children**

There is a long history connecting temporal lobe epilepsy with memory disturbances (Tissot, 1770). Indeed, subclinical discharges in the temporal lobe can disturb memory functions, and certain anti-epileptic drugs can exacerbate memory difficulties. In some instances, massive memory deficits in the context of child TLE may also be the consequence of neonatal hypoxia and subsequent MTL



damage (Gadian et al., 2000). Among the various factors likely to affect memory performance in LTE, the localization, frequency, and type of seizures, the characteristics of electroencephalographic anomalies, anti-epileptic drugs, and, more particularly, the age of onset of the disease, are classically incriminated with the progressive alteration of memory functions. Most retrospective studies also link febrile convulsions in infancy and the risk of developing medial-temporal lobe epilepsy. Thus, it remains challenging to distinguish memory deficits consecutive to the onset of seizures for long years and those which may exist earlier. Unlike DA, TLE is thus rarely a pure developmental pathology, but most frequently a mix between developmental and acquired pathology anomalies. The impact on memory can be detected during the early development of memory functions or at a later stage and be associated with deterioration. Thus, the exploration of memory deserves special attention in children or adolescents who have epilepsy, also given the frequent complaints later in life concerning difficulties in memorizing or consolidating information in these patients when adults. However, it should be kept in mind that memory dysfunction in LTE is not necessarily isolated as for AD. Even though children with TLE generally have typical intellectual efficiency, there is a significant risk for language development in children who have developed refractory epilepsy of the left temporal lobe at an early age (Gleissner et al., 2003). Some authors have also pointed out the existence of executive function deficits in young patients with TLE due to the anatomo-functional connections between the MTL and the frontal cortex (Cormak et al., 2005).

### ***Episodic memory dysfunction***

Although the literature on memory impairment in children with epilepsy is still limited, it is now clearly recognized that episodic memory deficits can be identified from childhood in the context of TLE (Jambaqué et al., 2005). Back in 1993, Jambaqué and her colleagues were the first to undertake with Jean Louis Signoret a systematic study on memory performance in 60 children aged 7 to 14 years with different forms of epilepsy using a standard memory assessment (Jambaqué et al., 1993). These children were all right-handed and of an average intellectual level, but many of them faced academic difficulties. The authors have highlighted in this population a notable insufficiency of memory function with a slight increase in performance with age compared to that of a control group. On the contrary, they did not show any significant difference in memory performance according to the age of onset of the disease, the frequency of seizures or anti-epileptic treatment. Remarkably, the type of epilepsy was the primary determinant of the memory performance profile. Children with partial epilepsy - temporal and frontal - were faced with severe memory problems affecting the processes of encoding and recalling new information. Long-term memory efficiency as well as storage and memory consolidation, more especially using complex material, are impaired in children with temporal epilepsy (Jambaqué et al., 2001). In contrast, children with frontal epilepsy seem to be more concerned by deficits in encoding processes in connection with a failure to use relevant learning strategies and poor working memory (Hernandez et al., 2003). This observation of memory difficulties in these two forms of partial epilepsy tended to reflect the specific involvement of the temporal and frontal lobes in the development of episodic memory (Cycowicz, 2000).

Several studies have since confirmed that children with epilepsy represent a population at high risk of developing memory impairment. Due to the involvement of the hippocampal complex in TLE, episodic memory deficits are more severe in this type of epilepsy compared to other forms commonly found in children (Nolan et al., 2004). Interestingly, a large cross-sectional study has demonstrated the particular fragility of episodic memory by comparing memory assessment (items learning and recall) between 1156 patients with chronic TLE (aged 6 to 68 years) and 1000 control subjects (aged 6 to 80 years) (Helmstaedter & Elger, 2009). The main results showed a difference in developmental gains in the two groups. Patients made much smaller gains in the recall of newly learned material during childhood and adolescence, and learning performance peaked at an earlier age in patients (16–17 years) compared to controls (23–24 years). This lack of significant

developmental gains in episodic memory from childhood to adolescence was also evident in another longitudinal study (Gonzalez et al., 2012). Together, these findings suggest that children with TLE “grow into their deficits.” This conclusion contrasts with results of studies involving patients with DA, where memory deficits are generally evident from childhood rather than appearing later in teenage years (Vargha-Khadem et al., 1997, 2003). While DA patients have severe episodic memory deficits arising from neonatal bilateral hippocampal pathology, milder episodic memory deficits would result from unilateral TLE. They would come to light gradually, over the course of memory development, which continues to develop into adolescence.

### ***Unilateral TLE and material-specific memory deficits***

Research on so-called “material-specific” deficits represents an exciting approach to study the impact of TLE on the development of episodic memory. Back in 1969, Fedio and Mirsky were the first to demonstrate a dissociation between impairment of verbal or visual-spatial memory in children with left or right TLE, respectively, like what is reported in surgical adult patients. This inaugural work, therefore, made it possible to establish a link between memory function and hemispherical asymmetry and this from childhood. Since then, several studies have consistently confirmed this pattern of dissociation in children with unilateral temporal epilepsy. Jambaqué et al. (1993) were able to establish the existence of a material-specific effect from the calculation of an intra-individual variability index between verbal memory performance and visual memory performance, and this despite the absence of any significant difference between verbal and performance IQs within the same group of children. They also mentioned an association between the deficit of visual memory and the right temporal impairment appearing more consistent in children than in adulthood. Other studies have since reproduced similar results and suggested greater or lesser sensitivity of the influence of hemispheric specialization depending on the period of life (e.g., Nolan et al., 2004). Indeed, with the development of language, the recourse to a double visual-verbal coding during memory tests would increase, declining the influence of hemispheric specialization. In the surgical context, some studies detected visuospatial learning disabilities in children who underwent right temporal resection without objectifying a deficit in verbal learning situation in children who had left temporal resection (Hepworth & Smith, 2002).

However, there is still controversy regarding material-specific deficits in children with TLE. Indeed, several authors have not found specific memory deficits in children with left or right temporal epilepsy, and this, before or after surgery (e.g., Gonzalez et al., 2007). The first large group study in a population of 36 children and adolescents with LTE that explored before and after surgery did not report any worsening memory efficiency after temporal resection and any material-specific effect depending on the side of the resection (Mabbott & Smith, 2003). However, there was an exception for the situation of recognition of unfamiliar faces, which appeared less effective in subjects with right temporal epilepsy. As concerned the absence of material-specific effect in left TLE, it could result from an atypical representation of language in this case and thus alteration of the typical pattern of association with a disorder of verbal memory and left side (Gleissner et al., 2003 ; Saltzman-Benaiah et al., 2003). Furthermore, it is also possible that verbal memory deficits are less severe and less irreversible in the pediatric context. Finally, it could be that standard memory tests are not sufficiently sensitive to detect subtle deficits in children.

### ***More ecological assessment of episodic memory***

There is generally a gap between memory assessments proposed by pediatric neuropsychologists and memory performance in daily life situations. Thus, some studies aimed to introduce more ecological tools to assess multifaceted episodic memory in an environmental context. On the one hand, in the verbal domain, many memory tests are simplistic and do not propose an ecological learning situation. The most classical verbal episodic assessment corresponds to a progressive

learning situation of a list of words that requires memorization in several attempts with an immediate reminder of the list of words and after a delay usually of around 20 minutes. This type of classical assessment has proved to be rather uninformative in many studies conducted in children and adolescents evaluated in the context of temporal lobe surgery. Thus, several studies mention fairly good performance obtained by TLE patients with this type of verbal memory task (e.g., Mabbott & Smith, 2003). By contrast, recalling a story or person's names seems more sensitive to characterize an impairment of verbal memory function in children and adolescents with left temporal epilepsy (Sperling et al., 2003; Jambaqué et al., 2007). On the other hand, standard visual tests such as recall, and recognition of abstract figures, are less sensitive to a dysfunction in the right temporal lobe than recognizing unfamiliar faces or recalling a complex visual scene or a walk.

All these more ecological memory materials most often correspond to the encoding of information presented as closer to the complexity of material present in every-day life. In the same line, several recent works have emphasized the relevance of the associative learning situation to identify an alteration in episodic memory in children and adolescents with TLE, and this either with verbal (word pairs) or non-verbal material (recall of objects and their location). Thus, it is suggested that tests with an associative learning component may be discriminating because of the dependence of associative memory on the hippocampus (Borden et al., 2006; Gonzalez et al., 2007; Picard et al., 2012, 2014). In the same line, it would be more sensitive to carry out delayed recall tests after a long delay after 24 hours or even a week (Cronel-Ohayon et al., 2006).

Memory assessments in situations of simulation of daily-life activities that target unique events and requiring the recall of specific details related to the encoding context are particularly crucial for detecting an episodic memory deficit in children with TLE, as in DA. By employing the Rivermead Behavioral Memory Test to understand better the impact of memory problems in daily life in children and adolescents after surgery for TLE, it reveals notable difficulties in remembering a journey, an appointment, and the name of a person (Jambaqué et al., 2007). In the same line, using material with emotional valence has proved to benefit the ecological interest of neuropsychological evaluation in LTE (Jambaqué et al., 2009). Weak skills in this type of test highlight the negative impact of memory deficits in daily life and personal memory. It can indeed be a better indicator than performance on standard tests of the extent of difficulties in remembering new information and instructions, remembering previously learned material, but also remembering recent or remote autobiographical events. To date, it thus seems necessary to propose ecological memory situations making it possible to better identify shortcomings during the various steps from encoding, consolidation, and retrieval of information. It is, therefore, required to develop more sophisticated tools taking into account the different facets of the definition of episodic memory to investigate the spatio-temporal and self-referential context related to the formation of memories as well as the state of consciousness associated with recall or recognition.

Binding capacities are crucial for a rich episodic memory trace, and they depend on the hippocampal circuit. However, they are still little evaluated in TLE in children, and pre- and postoperative neuropsychological evaluation. Yet, it can be possible through ecological what-where-when memory tests where the participant has to memorize not only the factual information (what) but its link with external spatio-temporal details (where and when) and internal perceptual and emotional details (how). For instance, a study evaluated binding capacities asking children with TLE to memorize associations between an animal presented via photo, and respectively a picture of one of its features, its location in an array, or its order of presentation (Martins et al., 2015). A significant alteration was found in associative memory, regardless of the lateralization, and patients with hippocampal sclerosis were the most deficient in binding capacities. Yet, the 3D technologies allow creating naturalistic versions of what-where-when memory task, which are ecological and very playful for children but allowing a strict experimental control. Our team is conducting a study in right or left LTE

children using a virtual what-where when task assessing incidental memory for everyday situations experimented in a virtual environment (e.g., walking in a town enriched with many shops and events), previously adapted for children and adolescents (Picard et al., 2017). Preliminary results reveal massive long-term feature binding deficit (recall of each specific event specifying the perceptual details and the spatial and temporal contexts) in both left and right LTE.

In the same line of interest, autobiographical memory appears to be particularly sensitive to episodic memory deficits in TLE. Frequently, children with TLE express difficulties in recalling past personal events (Smith et al., 2006; Piolino & Jambaque, 2003). The first study that investigated this issue in children with TLE provided experimental evidence of episodic autobiographical memory deficits (Gascoigne et al., 2013). Indeed, compared to 24 healthy controls, 21 children with TLE between 6 and 16 years of age recalled fewer episodic details (e.g., sensory-perceptive, affective or spatiotemporal details of personal events), but only in the case of no retrieval prompts provided, while there was no group effect for semantic elements (e.g., dates, names of persons, addresses). The left- and right-TLE groups did not differ on any demographic variables, verbal and visual memory test, and their recall of episodic details. Furthermore, epilepsy factors, including the presence or absence of structural hippocampal abnormalities, did not relate to the richness of episodic recall. However, unlike healthy control children (Picard et al., 2009, 2012; Piolino et al., 2007), the number of episodic details recalled did not increase significantly from 6 to 16 years of age in the children with TLE. According to the authors, the findings raise the possibility that the contralateral hippocampus or temporal structures that surround the abnormal hippocampus may support some episodic autobiographical memory in children, but not in adolescents with unilateral TLE. They suggest that older children/adolescents with TLE are at high risk of episodic autobiographical memory deficits but underestimated until now. This risk is critical as autobiographical memory plays a significant role not only in the construction of identity, but also in everyday life and adaptive functioning such as social problem-solving, and more generally on the quality of life. Thus, early diagnosis and intervention that enhances the consolidation and retrieval of autobiographical memories are likely to be important for children and adolescents with TLE. In this line, we know that adults with TLE started in childhood do not show a reminiscence bump for the period of adolescence, considered as a critical element for building self-identity (Múnera et al., 2014). Adults with right or left temporal lobe resection in the context of pharmaco-resistant LTE also present massive impairments of episodic autobiographical memory that covers their entire lifespan (Noulhiane et al., 2007). Epileptic factors may have a cumulative but gradual impact on the formation and retrieval of autobiographical memories that increase until adulthood. This issue deserves particular attention as a fragile autobiographical memory does not favor the construction of the sense of self, and the occurrence of seizures may represent in itself "a traumatism " in the personal experience of the child suffering from TLE.

### ***Prognosis of temporal lobe surgery in memory dysfunctions***

The first studies on the evolution after surgical treatment of TLE in children have shown an improvement in cognitive prognosis and behavioral adaptation (Davidson & Falconer, 1975; Lindsay, Ounsted & Richards, 1984; Meyer et al., 1986). This line of research also mentioned better academic learning capacities but omitted an evaluation of memory functions. The perioperative assessment of memory in young patients has gradually developed over the past decades in conjunction with the development of this therapeutic approach from childhood. Nowadays, temporal epilepsy surgery is recognized to improve the prognosis for crises. However, the assessment of memory skills reveals deficits that continue over time and eventually increased, depending on the age, area, and larger volume of temporal resection and the side of the resection. These aspects could explain some inconsistencies of the literature regarding marked memory deficits (Helmstaedter et al., 2011). Several studies have reported more severe memory disturbances in surgical adult patients who

started TLE before the age of 5 years compared to patients who developed this disease later (Herman et al., 2002, Lespinet et al., 2002). However, to date, the literature reports contradictory results in connection with methodological limitations concerning both the choice of memory tests and the difficulties encountered in forming homogeneous groups of patients in the pediatric population. Since children and adolescents who are candidates for surgery are rarer than in adulthood, the majority of studies include subjects of various ages - between six and eighteen years of age – different manual dominance and for whom it is not always possible to use the same assessment tools (Gleissner et al., 2002 ; Lewis et al., 1996; Mabbott & Smith, 20003 ; Robinson et al., 2000).

Standard evaluation of episodic memory seems to remain relatively stable after surgery in comparison with preoperative levels, or even to improve (Mabbott & Smith, 2003; Beaton et al., 2012; Skirrow et al., 2014; Lah & Smith, 2015; Flint et al., 2017). Some studies have mentioned little change, or even some improvement, in verbal memory (Lendt et al., 1999 ; Robinson et al., 2000; Kuehn et al., 2002), while some others reported a decline in this area (Adams et al., 1990 ; Szabo et al., 1998 ; Williams et al., 1998), like in visuospatial memory (Helmstaedter & Lendt, 2001; Hepworth & Smith, 2002). Interestingly, some research reported a decrease in verbal memory performance in young patients three months after left temporal resection but improvement after a delay of 1 year post-operative when they were less than 16 years old (Gleissner et al., 2005). In the same line, Jambaqué and her colleagues (2007) carried out a perioperative evaluation of memory functions in twenty right-handed children, aged 7 to 14, with an IQ higher than 80 and released from their seizures after left or right antero-medial temporal resection. These children were explored in the pediatric neurosurgery unit of the Rothschild Foundation in Paris and seen again about a year after surgery using a standard battery of neuropsychological evaluation, including measures of verbal and visuospatial memory. These children with TLE showed poor memory performance before surgery and tended to improve about one year after surgery. Significant differences were observed in verbal memory scores (learning of word lists, immediate recall of history, recognition of sentences), although the gain in verbal memory tended to be higher in children with left hippocampal atrophy before temporal resection. This study, like others (Mabbott & Smith, 2003; Gleissner et al., 2005), reveals a more favorable prognosis in the pediatric population than in adulthood after temporal resection, suggesting higher reorganization capacities ( Seidenberg et al., 1997; Richardson et al., 2003 ). This possibility of reorganization seems more consistent for verbal memory processes than for visual memory in pediatric subjects. There appears to be a strong relationship between the age of surgery and the post-surgical development of verbal episodic memory.

In the future, it will be critical to use more ecological assessment of the critical properties of episodic memory more insightful of everyday performance (Lou Smith & Lach, 2006), to substantiate the insights on the evolution of episodic memory function after post-surgery. The evaluation of surgical treatment of TLE in children must, therefore, consider the typical memory development expected with age and increasingly sophisticated skills of the episodic memory system (i.e., binding, auto-noetic consciousness, autobiographical memories). Accordingly, episodic memory evaluated by the Rivermead Behavioral Memory Test, appears deficient in children after surgery for temporal epilepsy (Jambaqué et al., 2007). In the same line, the reliance on familiarity, more than on recollection, is found in recognition of facial emotions in children after resection of the medial temporal lobe (Pinabiaux et al., 2013). Recently, Miró et al. (2019) report possible compensation of extra-temporal areas after resection that can take over for the operation of the autobiographical memory, but possibly revealing an improvement based on the semantic components rather than the episodic components of autobiographical memory (Martinelli et al., 2012). Finally, the pediatric context still raises questions about the time that can be considered sufficient - from a few months to several years - to assess the prognosis on the memory level. Moreover, given the existence of extra-mnesic function deficits described in young patients with TLE, it is also essential to assess the evolution of attentional skills and working memory and language after surgery (Jambaqué et al., 2007).

## **Remediation of memory dysfunction in children with DA and TLE**

Memory problems can compromise the path to independence and have an impact on the quality of life of the child with memory dysfunctions and his family. Child patients are not always expressing memory complaints in their daily life or during clinical assessments, but some of them also apologize for no memory or forgetting what we just told them. Parents also insist on learning problems in everyday life and regularly mention a certain slowness in learning and memory vagueness of daily life situations. In the same way, parents of DA or TLE children stress the efforts required and the importance of repetition in a learning situation, while teachers are often surprised by the lack of retention of information supposedly acquired beforehand.

In both pathologies, the memory evaluation can represent a first therapeutic step by revealing the pattern of memory difficulties while allowing to discuss the problems encountered during the memory tests, or at school and in daily life. The neuropsychological evaluation allows to inform the child and the parents on the consequences of an early anoxic episode or temporal epilepsy on the development of memory functions. A pedagogical adaptation, especially at school, can also be useful or at least the enunciation of a certain number of recommendations aimed at facilitating learning (Guillery-Girard et al., 2004; Besag, 2006). When memory deficits are objectified, it may also be necessary to consider memory remediation (Shulman & Barr, 2002; Ponds & Hendricks, 2006). By contrast with DA, the memory disorders are not always permanent in TLE and may have a discontinuous appearance depending on the control of the crises thanks to anti-epileptic medication or surgical treatment. In both cases, the children must learn how to optimize their memory skills, sometimes in addition to other dysfunctions. It is also necessary to consider the personality traits of the children and their emotional reactions to memory dysfunctions.

### ***Developmental amnesia***

The care of patients with DA has been the subject of several works based on reeducation techniques in adults with an amnesic syndrome such as facilitating the encoding or retrieval of information, exploiting intact memory systems (semantic memory, implicit memory) or developing the environment with supports (post-it, calendar, alarms, photos...). A child with marked episodic memory deficits must perform deliberate learnings exclusively relying on semantic memory, reasoning, and deduction skills. Specific learning techniques, known as "errorless learning" and favoring the acquisition of semantic knowledge despite a severe episodic memory disorder, have also proved to be relevant in DA. Several studies in children proposed personalized protocol to see if DA can benefit from multimodal facilitation techniques such as blurring or blending for learning, errorless learning, double encoding and manipulation of material for characteristics learning, or repetition of information. For instance, the errorless learning method was tested in two children with DA on four successive sessions of double encoding method (texts and images) and retrieval (naming and multiple-choice recognition) regarding eight unknown concepts (e.g., the name of an animal and its characteristics), (Guillery-Girard et al., 2004; Martins et al., 2006). The authors showed learning capacities despite the absence of memory of the different learning sessions, but more slowly than a group of healthy children. Adding the blending technique appears particularly useful since the denomination task did not significantly differ in the two DA patients from those of controls. In general, all the studies confirm that DA patients can acquire new learnings but need more sessions to reach the level of controls. In addition, how the patients are questioned (recognition versus recall) facilitates access or not to this new knowledge by reducing the involvement of episodic memory. Therefore, the families and teachers at school can benefit from these training methods that facilitate explicit memory in DA. In everyday life, more generally, it is noticeable that DA patients need external aids and social-environmental support, especially for managing contextual constraints and

all changes in routines. Proposing classic learning techniques and daily life accommodations can be the basis of the quality of life improvements in DA and be compatible with future professional activities and social life. Finally, as episodic memory deficit in DA also involves the breakdown of episodic autobiographical memories, a training program may also propose strategies to facilitate the storage of personal memories across the entire lifespan to improve social adaptation, autonomy, and sense of self. Some compensatory strategies were spontaneously set up by Valentine's to improve her social adaptation. Indeed, she had taken the habit of taking pictures of all the significant events in her life. Thus, when asked about these, she could bring about change by providing details, in fact, describing by memory the photos. Sensecam has also been used to help severe anterograde amnesic patients to keep in mind some of their new personal experiences. Sensecam is a wearable camera that takes photos automatically of personal experience in a first-person perspective conceived as an individual 'Black Box' recorder. The repeated viewing of these images previously recorded tends to elicit the formation of personal semantic memories in children who have marked episodic memory difficulties (Pauly-Takacs et al., 2010).

### ***Temporal lobe epilepsy***

In contrast with young DA patients with bi-hippocampal lesions of hypoxic origin, academic difficulties are more frequent in children with TLE, even when their intellectual level seems satisfactory (Bulteau et al., 2000). In general, episodic memory deficits are less severe in children with TLE than with DA. By contrast, children suffering from TLE present some repercussions of their memory disturbances on school performance and the acquisition of general knowledge, even if most of the children follow a regular education or may experience a delay in the schooling of at least one year. Hence, TLE young patients can express spontaneous difficulties in situations of naming, learning, and retaining their lessons of poetry, history-geography, or natural sciences. These difficulties are more severe in those with left TLE who can be more concerned than right TLE with problems of vocabulary learning, reading, intentional memorization for verbal material, and semantic memory. So, in contrast with DA, the co-existence of episodic and semantic memory disorders is all the more possible in TLE since many children present a pathology affecting both the hippocampal formation and the temporal neocortex (Temple, 1997; O'Reilly & Norman, 2002; Lah & Smith, 2014). It is, therefore, necessary to assess both episodic and semantic memory in children with TLE, especially epilepsy of the left temporal lobe (Jambaqué & Chmura, 2006).

Yet, there are no standard training programs to restore memory function in the children with TLE, but as for DA, learning techniques and environmental supports used in adults may be useful in these children. Hence, rehabilitation may involve the child, his family, and his educators to promote a better adaptation in daily life. It is appropriate for the child and his family to set out daily routines aimed at improving memory efficiency adapted for TLE child: being attentive allows better encoding processing of information, organization of information as well as planning and repetition are likely to improve memory performance. All situations (e.g., story, reading, film, photo album, videos) that could be the pretext for asking questions about old or new information and inviting the child to refresh and remember information would be of benefit for the child with TLE (Jambaqué, 2005). Even though in DA, this procedure would improve performance, not via recollection and associative processes, but familiarity and schematic processes, it should elicit some residual vivid episodic memory performance in TLE. In the same line, main objectives of rehabilitation in TLE patients with memory deficit memory will encourage the use of external help such as an "alarm" watch or the use of a pictorial calendar, and promote the use of visuospatial or verbal strategies for better memory (e.g., mental imagery technique, PQRS (Preview, Questions, Read, State, Test) method). Children with LTE could benefit from learning to search for context-related information by systematically asking questions of what? , where? , when? , who?, or by referring new information to themselves ("Does this remind me of personal experience?", "Is it important to me?"). These procedures could stimulate encoding processes of new information or events via residual medial temporal areas

(feature binding processes, Olsen et al., 2012; Olson & Newcombe, 2013) or extra-temporal lobe areas such as the medial prefrontal cortex (self-referential processes, Symons & Johnson, 1997; Martinelli et al., 2013). Finally, as TLE children may experience signs of depression and anxiety, and low self-esteem, psychological supports may be necessary to encourage them in their efforts and help them find the required energy to develop strategies in their memory activities and daily life.

## **Conclusion and future directions**

Memory problems in children have generated less research than in adult patients. The evaluation of memory has long been confused with that of intelligence in children (Jambaqué, 2017). Up until the early 1990s, there have been few psychometric tools for exploring memory processes in the pediatric population. Also, the memory complaint is less explicit in young patients due to a certain immaturity limiting awareness of memory disorders and greater dependence on the family environment that can mask difficulties in daily life, especially before schooling. Hence, school-age is often the occasion to discover memory deficits. As a result, school learning problems are over-represented in this population. Their parents, like their teachers, generally express specific questions concerning the existence of possible memory disturbances, and for a better understanding of the problems encountered by the children in learning behaviors as well as forgetting phenomena in daily life (Fastenau et al., 2004).

The prevalence of pure developmental amnesic syndrome in children seems rare, but nowadays, researchers consider that there could be an underestimation of a pediatric population with severe memory deficits consequent to brain damage. Some neonates undergoing treatment for acute respiratory failure might sustain bilateral hippocampal pathology early in life and memory problems later in childhood or adolescence. The neonatal or early bi-hippocampal lesions of hypoxic origin and early epilepsy of the left or right temporal lobe - before or after surgery represent " high risk " situations on the domain of neuropsychology of memory. In the most severe forms, like developmental syndrome amnesia, a severe isolated and permanent deficit in long-term and explicit memory, particularly affecting episodic memory and preserving semantic memory. Developmental amnesia, therefore, represents a study model for the development of memory systems and confirms the critical role of hippocampal regions in new learning, binding processes, recollection, and the constitution of autobiographical memories. In the case of children with right or left temporal lobe epilepsy, which is relatively frequent compared to developmental amnesia, an alteration of episodic memory is also prevalent. Hence, temporal lobe epilepsy represents a primary source of information for the study of hemispheric specialization of memory, developmental brain vulnerability, and compensatory functional plasticity. Given the fact that lesions or surgery in TLE also concern extra-medial temporal regions, episodic memory deficits are not so isolated than in DA as they may be associated with other deficiencies regarding semantic memory, executive functions, and language.

Early recognition of memory disorders is essential in children given the developmental trajectory of memory throughout childhood and adolescence, and the consequences in learning and development of other complex cognitive functions such as social cognition, sense of identity, and autonomy in daily life. One of the most critical challenges in the pediatric population with memory dysfunctions is to pursue the development of new tools for the evaluation of episodic memory, covering all the characteristics of this memory system, sensitive to difficulties in daily life and adapted to children of different ages. The ecological validity of assessment instruments is an essential issue in neuropsychology to capture the essence of the cognitive demands in the everyday environment thanks to measures of real-world functioning. In the future, this approach typically will require combining the existing standard tests with new tests with higher ecological validity. In the specific domain of memory functions in daily life, new technology using virtual reality seems particularly



helpful for creating innovative controlled memory assessments and remediation programs. Some single case studies have provided new avenues of research for the development of remediation strategies to improve new learnings and retrieval capacities in AD and LTE. Thus, a second challenge will be to increase the provision of care for episodic memory disorders in the pediatric population to improve schooling learning, compensation strategies, and autonomy in daily life. The consequences of memory dysfunctions in education and psychosocial dimensions and everyday life require multidisciplinary care, with a neuropsychological approach and brain exam, in conjunction with medical treatments when possible (e.g., anti-epileptic treatment), as well as educational adaptation and family support.

## Box 1. Valentine case history: a case of developmental amnesia

Valentine is a smiling girl who suffered anoxia at birth that led to bilateral atrophy of the hippocampus. Her developmental milestones were typical, and she attended mainstream schools. Nevertheless, at the age of 10, Valentine developed a form of epilepsy that failed to respond to drug treatment. At the age of 13.5, neurological and neuropsychological exams were suggested, given her parents' complaints concerning essentially visuospatial disorientation. A diagnostic of developmental amnesia concluded this first evaluation.

Valentine's parents reported that their daughter presented the inability to find her way in familiar surroundings reliably, or difficulties in remembering where she put objects. When asked for Valentine's memory in daily life, they reported a good memory for songs or poems but described some problems such as vagueness, amalgams of different events in one memory and source memory difficulty. At that time, the neuropsychological assessment revealed preserved intelligence, language, semantic and working memory abilities but altered visuospatial skills and severe deficits with episodic memory tasks (Children Memory Scale, CMS, Cohen, 2001: e.g., total index 50, norm  $100 \pm 15$ ).

At the time 18 years old, Valentine has obtained quite good scholarly results in a business school, but she had to work a lot to reach that level. She always showed vast spatial disorientation and episodic memory problems. Consequently, Valentine failed to become autonomous during her first work experience in a company. She lived with her parents in a very protective environment, and she has no close friends, but she has no complaint about this situation. She has no clear specific project for the future ("I will be married like my brother"). At that time, there was a brain scan (Table 1) and second neuropsychological assessment, which indicated a similar pattern of performance as the first neuropsychological assessment: preservation of verbal reasoning, mental imagery, semantic memory, short-term feature binding, and working memory as well as executive functions (inhibition and shifting), but an alteration of visuoconstructive skills and verbal and visual episodic memory (respectively Rey Auditory Verbal Learning Test and Rey Visual Design Learning Test) revealing weak but not null learning abilities as well as delayed recall and better recognition.

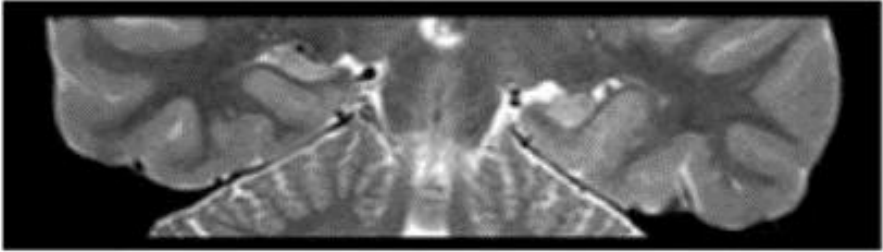
More ecological and complete episodic memory tests allowed to examine the ability to retrieve long-term feature binding in daily life (what-where-when-details association).

- First, we use the House test (Picard et al., 2012) which evaluates the capacity to memorize a series of daily life activities from the morning until the evening presented as what-where-when narrative contents ("in the morning, after she got dressed, she poured water into the aquarium, in the kitchen). During the incidental encoding phase, the participant must show pictures that illustrate each activity and indicate the correct time and place. Then we tested delayed free and cued recall, sense of remembering via re-experiencing or just knowing, and recognition.
- Second, we used a virtual reality episodic memory (VREM) test (Picard et al., 2016) to examine episodic memory in a naturalistic encoding situation, that includes the intentional encoding of visuospatial scenes (e.g., pass a with jets of water fountain in a park) during the navigation in a virtual town, and the recall of these scenes with perceptual details and their spatiotemporal context (what-details-where-when).
- Third, we use an adaptation of the TEMPau task (Piolino et al., 2006, 2009) to measure episodic and semantic autobiographical components according to different lifetime periods (infantile period (first 5 years of life), childhood (ages 5 to 10), adolescence (age > 10), last school year and current school year).

The results of this evaluation indicated dramatic long-term feature binding deficits regardless of the method of testing (free recall, cued recall or recognition, and intentional or incidental encoding), (see

Figure 1). Finally, similar feature binding alteration concerned episodic autobiographical memory while preserving the sense of knowing and personal semantic knowledge (see Figure 2).

Table 1. Valentine’s brain MRI scan and atrophy



Volumetric measurement (in mm <sup>3</sup> )	Left hemisphere	Right hemisphere
Hippocampal formation	1034**	1037**
Temporopolar cortex	1592**	1632**
Perirhinal cortex	2678	2198
Entorhinal cortex	1150*	1192*

\*limit values : between -1SDs and -2SDs from the controls’ mean  
 \*\*severely abnormal values : less than 2SD from the controls’ mean  
 Control group and method described in Bindschaedler et al., Cortex, 2011).

Figure 1. Valentine’s results of the evaluation of long-term feature binding in new learning

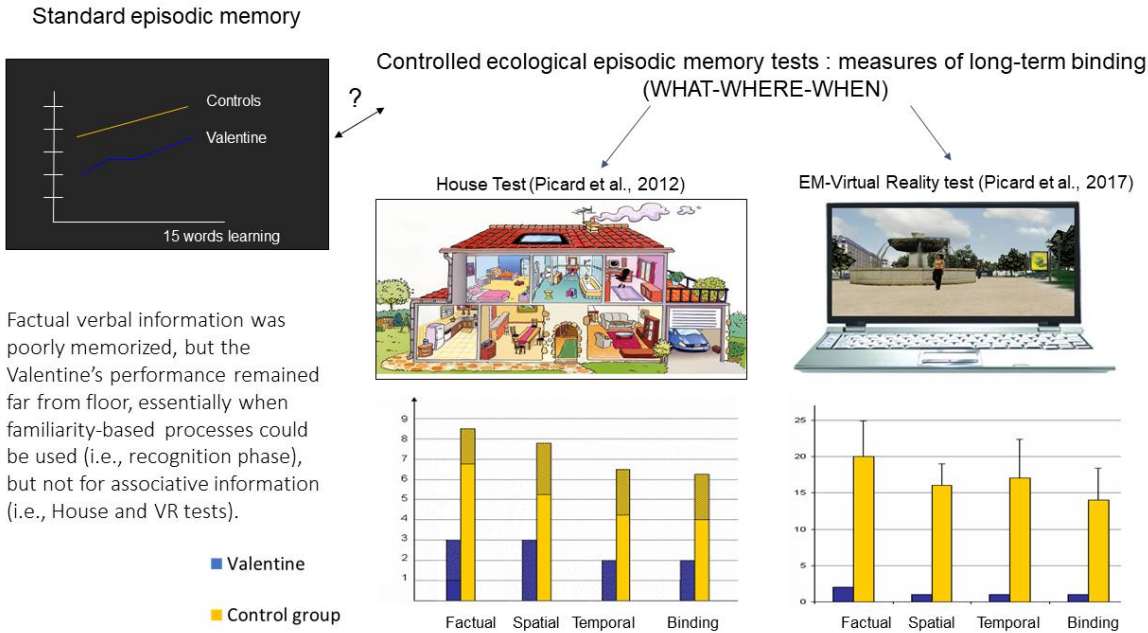
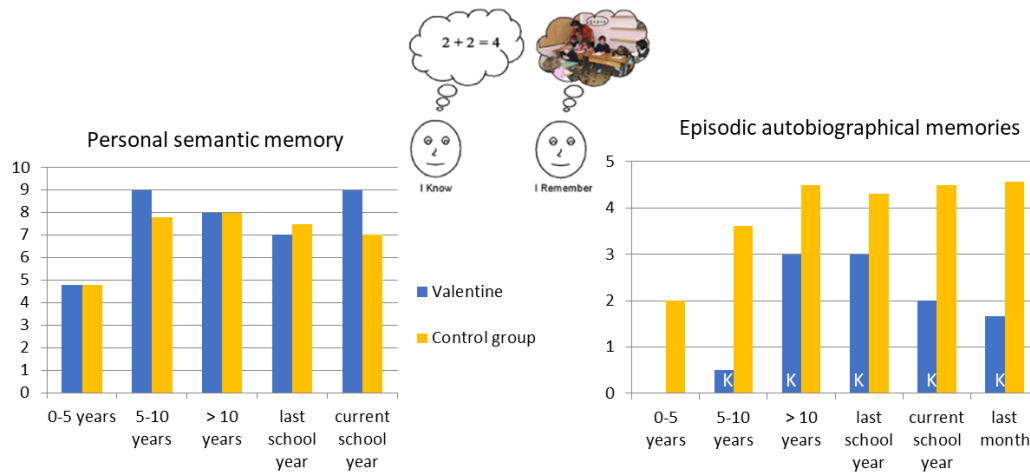


Figure 2. Valentine's results of the evaluation of autobiographical memory

## Dissociation within autobiographical memory (TEMPau task, Piolino et al., 2006)



### ***Bibliographic references***

Adams, C.B.T., Beardsworth, E.D., Oxbury, S.M., et al. (1990). Temporal lobectomy in 44 children: outcome and neuropsychological follow-up. *Journal of Epilepsy*, 3 (suppl), 157-168.

Adlam, A.L.R., Malloy, M., Mishkin, M., et al. (2009). Dissociation between recognition and recall in developmental amnesia. *Neuropsychologia*, 47, 2207-10.

Aggleton, J.P., O'Mara, S.M., Vann, S.D., et al. (2010). Hippocampal-anterior thalamic pathways for memory : uncovering a network of direct and indirect actions. *Eur J Neurosci*, 31, 2292-307.

Baddeley A, Vargha-Khadem F, Mishkin M. (2001). Preserved recognition in a case of developmental amnesia: Implications for the acquisition of semantic memory? *Journal of Cognitive Neuroscience*, 13, 357–369. [PubMed: 11371313]

Beaton, A., Durnford, A., Heffer-Rahn, P., et al. (2012). Transylvian selective amygdalohippocampectomy in children with hippocampal sclerosis: Seizure, intellectual and memory outcome. *Seizure*, 21(9), 699-705.

Besag, F.M. (2006). Cognitive and behavioral outcome of epileptic syndromes : implications for education and clinical practice. *Epilepsia*, 47, 119-125.

Bindschaedler, C., Peter-Favre, C., Maeder, P., et al . (2011). Growing up with bilateral hippocampal atrophy: from childhood to teenage . *Cortex*, 47, 931-44.

Borden, KA, Burns, TG, & O'Leary, S.D. (2006). *Child Neuropsychology*, 12 , 165-172.

Brandt, K.R., Gardiner, J.M., Vargha-Khadem, F., et al. (2009). Impairment of recollection but not familiarity in a case of developmental amnesia. *Neurocase*, 15, 60-5.

- Brandt, K.R., Gardiner, J.M., Vargha-Khadem, F., et al. (2009). Impairment of recollection but not familiarity in a case of developmental amnesia. *Neurocase*, 15, 60-5.
- Brizzolara, D., Casalini, C., Montanaro, D., & Posteraro, F. (2003). A case of amnesia at an early age. *Cortex*, 39, 605-625.
- Broman, M., Rose, A.L., Hotson, G., et al. (1997). Severe anterograde amnesia with onset in childhood as a result of anoxic encephalopathy. *Brain*, 120, 417-433.
- Bulteau, C., Jambaqué, I., Viguier, D., et al. (2000). Epileptic syndromes, cognitive assessment and school placement: a study of 251 children. *Developmental Medicine Child Neurology*, 42, 319-327.
- Burns, P., Russell, J., & Russell, C. (2015). Children's Binding of What-Where-When-Who in Episodic Memory: Identifying Oneself in the Past. *Journal Of Cognition And Development*, 17(2), 300-319.
- Clusmann, H., Kral, T., Gleissner, U., et al. (2004). Analysis of different types of resection for pediatric patients with temporal lobe epilepsy. *Neurosurgery*, 54, 8847-8859.
- Conway, M.A. (2009). Episodic memories. *Neuropsychologia*, 47, 2305-2313.
- Cooper, J. M., Gadian, D. G., Jentschke, S., et al. (2015). Neonatal hypoxia, hippocampal atrophy, and memory impairment: Evidence of a causal sequence. *Cerebral Cortex*, 25, 1469-1476.
- Cooper, J.M., Vargha-Khadem, F., Gadian, D.G., Maguire, E.A. (2011). The effect of hippocampal damage in children on recalling the past and imagining new experiences, *Neuropsychologia*, 1843–1850.
- Cormak, F., Gadian, DG, Vargha-Khadem, F., et al. (2005). Extra-hippocampal gray matter density abnormalities in pediatric mesial temporal sclerosis. *Neuroimage*, 27, 365-643.
- Cormak, F., Vargha-Khadem, F., Wood, SJ, et al. (2012). Memory in pediatric temporal lobe epilepsy : effects of lesion type and side. *Epilepsy Research*, 98 (2-3), 255-259.
- Cronel-Ohayon, S., Zeziger, P., Davidoff, V., et al. (2006). Deficit in memory consolidation (abnormal forgetting rate) in childhood temporal lobe epilepsy. *Neuropediatrics*, 37, 317-324.
- Davidson, S., & Falconer, M. (1975). Outcome of surgery in 40 children with temporal lobe epilepsy. *Lancet*, 1, 1260-1263 .
- Düzel, E., Vargha-Khadem, F., Heinze, H.J., et al. (2001). Brain activity evidence for recognition without recollection after early hippocampal damage. *Proc Natl Acad Sci USA*, 98, 8101-6.
- Fastenau, P.S., Shen, J., Dunn, D.W., Perkins, S.M., Hermann, B.P., Austin, J.K. (2004). Neuropsychological predictors of academic underachievement in pediatric epilepsy: moderating roles of demographic, seizure, and psychosocial variables. *Epilepsia*, 45, 1261-1272.
- Fedio, P., & Mirsky, A.F. (1969). Selective intellectual deficits in children with temporal lobe or centrencephalic epilepsy. *Neuropsychologia*, 7, 287-300.
- Flint, A., Waterman, M., Bowmer, G., et al. (2017). Neuropsychological outcomes following paediatric temporal lobe surgery for epilepsies: Evidence from a systematic review. *Seizure*, 52, 89-116.
- Fogarasi, A., Tuxhorn, I., Jansky, I., et al. (2007). Age-dependent seizure semiology in temporal lobe epilepsy. *Epilepsia*, 48, 1697-1702.
- Gadian, D.G., Aicardi, J., Watkins, K.E., et al. (2000). Developmental amnesia associated with early hypoxic-ischaemic injury. *Brain*, 123, 499-507.

- Gardiner, J.M., Brandt, K.R., Baddeley, A.D., et al. (2008). Charting the acquisition of semantic knowledge in a case of developmental amnesia. *Neuropsychologia*, 4, 2865-8.
- Gardiner, J.M., Brandt, K.R., Vargha-Khadem, F., et al. (2006). Effects of level of processing but not of task enactment on recognition memory in a case of developmental amnesia. *Cognitive Neuropsychology*, 23, 930–948.
- Gascoigne, M., Smith, M., Webster, R., et al. (2013). Autobiographical Memory in Children with Temporal Lobe Epilepsy. *Journal Of The International Neuropsychological Society*, 19(10), 1076-1086.
- Gleissner, U., Kurthen, M., Sassen, R., et al. (2003). Clinical and neuropsychological characteristics of pediatric epilepsy patients with atypical language dominance. *Epilepsy & Behavior*, 4, 746-752.
- Gleissner, U., Sassen, R., Lendt, M., et al. (2002). Pre-and postoperative verbal memory in pediatric patients with temporal lobe epilepsy. *Epilepsy Research*, 51, 287-296.
- Gleissner, U., Sassen, R., Schramm, J., et al. (2005) Greater functional recovery after temporal lobe epilepsy surgery in children. *Brain*, 128, 2822-2829.
- Gonzalez, L.M., Embuldeniya, U.S., Harvey, A.S., et al. (2014). Developmental stage affects cognition in children with recently-diagnosed symptomatic focal epilepsy. *Epilepsy & Behavior*, 39, 97-104.
- Guillery-Girard, B., Martins, S., Parisot-Carbuccia, D., et al. (2004). Semantic acquisition in childhood amnesic syndrome: a prospective study. *Neuroreport*, 15, 377-81.
- Guimaraes, C.A., Li, L.M., Rzezak, P., et al. (2007). Temporal lobe epilepsy in childhood: Comprehensive neuropsychological assessment. *Journal of Child Neurology*, 22, 836-840.
- Helmstaedter, C., & Elger, C.E. (2009). Chronic temporal lobe epilepsy: A neurodevelopmental or progressively dementing disease? *Brain*, 132(10), 2822–2830. doi:10.1093/brain/awp182
- Helmstaedter, C., & Lendt, M. (2001). Neuropsychological outcome of temporal and extratemporal lobe resections in children. In : Jambaqué, I., Lassonde, M., & Dulac, O., editors. *Neuropsychology of Childhood epilepsy*. Advances in behavioral biology, vol 10, New York : Kluwer Academic / Plenum Publishers, p; 215-227.
- Hepworth, S., & Smith, M.L. (2002). Learning and recall of story content and spatial location after unilateral temporal-lobe excision in children and adolescents. *Child Neuropsychology*, 8, 16-26.
- Hermann, B.P., Seidenberg, M., Bell, B. (2002). The neurodevelopmental impact of childhood onset temporal lobe epilepsy on brain structure and function and the risk of progressive cognitive effects. *Progress Brain Research*, 135, 429-438.
- Hurley, N.C., Maguire, E.A., Vargha-Khadem, F. (2011). Patient HC with developmental amnesia can construct future scenarios. *Neuropsychologia*, 49, 3620-8.
- Isaacs, E.B., Vargha-Khadem, F., Watkins, K.S., et al. (2013). Developmental amnesia and its relationship to degree of hippocampal atrophy. *Proc Natl Acad Sci USA*, 100, 13060-3.
- Jacoby, L.L. (1991). A process dissociation framework: Separating automatic from intentional uses of memory. *Journal of Memory and Language*, 30, 513–541.
- Jambaqué, I. (2005) Epilepsy and Memory in children. In : Hommet, C., Jambaqué, I., Billard, C., Gillet, P. (Eds) *Child neuropsychology and developmental disorders*, (pp. 325-348), Marseille: Solal.
- Jambaqué, I. (2017). Emergence, structuration et reconnaissance de la neuropsychologie de l'enfant. In : Roy, A, Guillery-Girard, B., Aubin, G., Mayor, C. (Eds). *Neuropsychologie de l'enfant*, DeBoeck, Louvain-La-Neuve. pp. 5-23.

- Jambaqué, I., Chmura, S. (2006) The evaluation of memory in children with epilepsy. *Epilepsies* , 18 : 32-37
- Jambaqué, I., Dellatolas, G., Dulac, O., et al. (1993). Verbal and visual memory impairment in children with epilepsy. *Neuropsychologia*, 31, 1321-1337.
- Jambaqué, I., Dellatolas, G., Fohlen, M., et al. (2007). Memory functions following surgery for temporal lobe epilepsy in children. *Neuropsychologia* , 45: 2850–2862.
- Jambaqué, I., Hertz-Pannier, L., Mikaeloff, Y., et al. (2006). Severe memory impairment in a child with bihippocampal injury after status epilepticus. *Developmental Medicine & Child Neurology* , 48, 223-226.
- Jambaqué, I., Lasseonde, M., Dulac, O. (2001). *Neuropsychology of childhood epilepsy*. New York: Kluwer Academic: Plenum Publishers.
- Jambaqué, I., Pinabiaux, C., Dubouch, C., et al. (2009) Verbal emotional memory in children and adolescents with temporal lobe epilepsy: a first study. *Epilepsy & Behavior*; 16, 69-75.
- Jambaqué, I., Pinabiaux, C., Lasseonde, M. (2013). Cognitive disorders in pediatric epilepsy. *Handbook of clinical neurology* , 111, 691-695. doi : 10.1016 / B978-0-444-52891-9.00071-3.
- Jonin, P.Y., Besson, G., Lajoie, R., et al. (2018). Superior explicit memory despite severe developmental amnesia: in-depth case study and neural correlates. *Hippocampus*, 28, 867-88.
- Irish, M., & Piguët, O. (2013). The Pivotal Role of Semantic Memory in Remembering the Past and Imagining the Future. *Front. Behav. Neurosci.*, 7, 27.
- Kuehn, S.M., Keene, D.L., Richards, P.M., et al. (2002). Are there changes in intelligence and memory functioning following surgery for the treatment of refractory epilepsy in childhood? *Child Nervous System*, 18 , 306-310.
- Kwan, D., Carson, N., Addis, D.R., et al. (2010). Deficits in past remembering extend to future imagining in a case of developmental amnesia. *Neuropsychologia*, 48, 3179-86.
- Lah, S., Smith, M.L. (2014). Semantic and episodic memory in children with temporal lobe epilepsy : do they relate to literacy skills ? *Neuropsychology* , 1, 113-122.
- Lah, S., & Smith, M. (2015). Verbal memory and literacy outcomes one year after pediatric temporal lobectomy: A retrospective cohort study. *Epilepsy & Behavior*, 44, 225-233.
- Lendt, M., Helmstaedter, C., & Elger, C.E. (1999). Pre and postoperative neuropsychological profiles in children and adolescents with temporal lobe epilepsy. *Epilepsia*, 40 , 1543-1550.
- Lespinet, V., Bresson, C., N'Kaoua, B., et al. (2002). Effect of age of onset of temporal lobe epilepsy on the severity and the nature of preoperative memory deficits. *Neuropsychologia*, 40 , 1591-1600.
- Lewis, D.V., Thompson, R.J., Santos, C.C., et al. (1996). Outcome of temporal lobectomy in adolescents. *Journal of Epilepsy*, 9 , 198-205.
- Lou Smith, M., Elliott, I., Lach, L. (2006). Memory Outcome After Pediatric Epilepsy Surgery: Objective and Subjective Perspectives. *Child Neuropsychology*, 12(3), 151-164.
- Mabbott, D.J., & Smith, M.L. (2003). Memory in children with temporal or extra-temporal excisions. *Neuropsychologia*, 41 , 995-1007.
- Maguire, E.A., Vargha-Khadem, F., Mishkin, M. (2001). The effects of bilateral hippocampal damage on fMRI regional activations and interactions during memory retrieval. *Brain*, 124, 1156-1170.

- Martinelli P, Sperduti M, Piolino P. Neural substrates of the self-memory system: new insights from a meta-analysis . *Hum Brain Mapp* 2013; 34: 1515-29.31 .
- Martins, S., Guillery-Girard, B., Jambaqué, I., et al. (2006). How children suffering severe amnesic syndrome acquire new concepts? *Neuropsychologia* , 44 , 2792-2805.
- Martins, S., Guillery-Girard, B., Clochon, P., et al. (2015). Associative episodic memory and recollective processes in childhood temporal lobe epilepsy. *Epilepsy & Behavior*, 44, 86-89.
- Meyer, F.B., Marsh, W.R., Laws, E.R. Jr., et al. (1986). Temporal lobectomy in children with epilepsy. *Neurosurgery*, 64 , 371-376.
- Miro, J., Ripolles, P., Sierpowska, J., et al. (2019). Autobiographical memory in epileptic patients after temporal lobe resection or bitemporal hippocampal sclerosis. *Brain Imaging And Behavior*.
- Moscovitch, D.A., & Mc Andrews, M.P. (2002). Material specific deficits in “remembering” in patients with unilateral temporal lobe epilepsy and excisions. *Neuropsychologia*, 41 , 1335-1342.
- Mullally, S.L., Vargha-Khadem, F., Maguire, E.A. (2014). Scene construction in developmental amnesia: an fMRI study. *Neuropsychologia*, 52, 1-10.
- Munera, C., Lomlondjian, C., Gori, B., et al. (2014). Episodic and Semantic Autobiographical Memory in Temporal Lobe Epilepsy. *Epilepsy Research And Treatment*, 2014, 1-9.
- Nolan, M. A., Redoblado, M. A., Lah, S., et al. (2004). Memory function in childhood epilepsy syndromes. *Journal of Paediatric Child Health*, 40, 20–27.
- Noulhiane, M., Piolino, P., Hasboun, D., et al. (2007). Autobiographical memory after temporal lobe resection: neuropsychological and MRI volumetric findings. *Brain*, 130(12), 3184-3199.
- Olsen, R.K., Lee, Y., Kube, J., et al. (2015). The role of relational binding in item memory: evidence from face recognition in a case of developmental amnesia. *J Neurosci*, 35, 5342-50.
- Olson, I. R., & Newcombe, N. S. (2013). Binding together the elements of episodes: Relational memory and the developmental trajectory of the hippocampus. *The Wiley handbook on the development of children's memory*, 1, 285-308.
- O'Reilly, R.C., & Norman, K.A. (2002). Hippocampal and neocortical contributions to memory: advances in the complementary learning systems framework. *Trends in Cognitive Sciences*, 6 , 505-510.
- Patai EZ, Gadian DG, Cooper JM, et al. (2015). Extent of hippocampal atrophy predicts degree of deficit in recall. *Proc Natl Acad Sci USA*, 112, 12830-3
- Pauly-Takacs, C., Moulin, C.J., Estlin, E.J. (2011). SenseCam as a rehabilitation tool in a child with anterograde amnesia. *Memory*, 19(7), 705-12.
- Picard, L., Abram, M., Orriols, E., Piolino, P. (2017). Virtual reality as an ecologically valid tool for assessing multifaceted episodic memory in children and adolescents. *International Journal of Behavioral Development*, 41(2), 211– 219.
- Picard, L., Cousin, S., Guillery-Girard, B., et al. (2012). How Do the Different Components of Episodic Memory Develop? Role of Executive Functions and Short-Term Feature-Binding Abilities. *Child Development*, 83(3), 1037- 1050.
- Picard, L., Mayor-Dubois, C, Maeder, P., et al . (2014). Functional independence within the self-memory system: new insights from two cases of developmental amnesia . *Cortex*, 49:1463-81.



- Picard, L., Reffuveille, I., Eustache, F., Piolino, P. (2009). Development of auto-noetic autobiographical memory in school-age children: Genuine age effect or development of basic cognitive abilities?. *Consciousness And Cognition*, 18(4), 864-876.
- Pinabiaux, C., Bulteau, C., Fohlen, M., et al. (2013). Impaired emotional memory recognition after early temporal lobe epilepsy surgery: The fearful face exception?. *Cortex*, 49(5), 1386-1393.
- Pinabiaux, C., Pannier, L., Chiron, C., et al. (2013). Memory for fearful faces across development: specialization of amygdala nuclei and medial temporal lobe structures. *Frontiers in human neuroscience*, 7, 901.
- Piolino, P., & Jambaqué, I. (2003). Developmental approach of autobiographical amnesia in epilepsy: study of 3 children after resection of the left temporal lobe. Posted communication Société de Neuropsychologie de Langue Française, Paris.
- Piolino, P., Hisland, M., Ruffevelle, I., et al. (2007). Do school-age children remember or know the personal past?. *Consciousness And Cognition*, 16(1), 84-101.
- Ponds, R.W.H.M. & Hendricks, M. (2006). Cognitive rehabilitation of memory problems in patients with epilepsy. *Seizure*, 15, 267-273.
- Richardson, M.P., Strange, B.A., Duncan, J.S., et al. (2003). Preserved verbal memory function in left medial temporal pathology involves reorganization of function to right medial temporal lobe. *Neuroimage*, 20, S112-S119.
- Robain, O. (1998). Neuropathology of childhood epilepsy. In: Arthuis, M., Pinsard, N., Ponsot, G., Dulac, O., Mancini, J. Pediatric neurology, pp 363-367, Paris, Flammarion.
- Robinson, S., Park, T.S., Blackburn, L.B., et al. (2000). Transparahippocampal selective amygdalo-hippocampectomy in children and adolescents: efficacy of the procedure and cognitive morbidity in patients. *Journal of Neurosurgery*, 93, 402-409.
- Rosenbaum, R.S., Gao, F., Honjo, K., et al. (2014). Congenital absence of the mammillary bodies : a novel finding in a well-studied case of developmental amnesia. *Neuropsychologia*, 65, 82-7.
- Saltzman-Benaiah, J., Scott, K., & Smith, ML (2003). Factors associated with atypical speech representation in children with intractable epilepsy. *Neuropsychologia*, 41, 1967-1974.
- Sander M.C., Werkle-Bergner, M., Gerjets, P., Lee Shing, Y., Lindenberger, U. (2012). The Two-Component Model of Memory Development, and Its Potential Implications for Educational Settings. *Review Dev Cogn Neurosci*, Suppl 1, S67-77.
- Scoville, W.B., Milner, B. (1957). Loss of recent memory after bilateral hippocampal lesions. *Journal of Neurology Neurosurgery & Psychiatry*, 20, 11-21.
- Seidenberg, M., Hermann, B.P, Schoenfeld, J., et al. (1997). Reorganization of verbal memory function in early onset left temporal lobe epilepsy. *Brain and Cognition*, 35, 132-148.
- Shulman, MB, & Barr, W. (2002). Treatment of memory disorders in epilepsy. *Epilepsy & Behavior*, 3, 30-34.
- Skirrow, C., Cross, J., Harrison, S., et al. (2014). Temporal lobe surgery in childhood and neuroanatomical predictors of long-term declarative memory outcome. *Brain*, 138(1), 80-93.
- Smith, M.L., Elliot, I.M., Lach, L. (2006). Memory outcome after pediatric epilepsy surgery: Objective and subjective perspectives. *Child Neuropsychology*, 12(3), 151-164.
- Squire, L. R. (2004). Memory systems of the brain: a brief history and current perspective. *Neurobiology of learning and memory*, 82(3), 171-177.

- Squire, L. R., & Zola, S. M. (1996). Structure and function of declarative and nondeclarative memory systems. *Proceedings of the National Academy of Sciences*, 93(24), 13515-13522.
- Symons, C., & Johnson, B.T. (1997). The Self-Reference Effect in Memory: A Meta-Analysis. *Psychological Bulletin*, 121(3), 371-94
- Szabo, C.A., Wyllie, E., Stanford, L.D, et al. (1998). Neuropsychological effect of temporal lobe resection in preadolescent children with epilepsy. *Epilepsia*, 39 , 814-819.
- Temple, C.M. (1997). Cognitive neuropsychology and its applications to children. *Journal of Child Psychology and Psychiatry*, 38 , 27-52.
- Temple, C.M., Richardson, P. (2006). Developmental amnesia : fractionation of developing memory systems. *Cogn Neuropsychol*, 23, 762-88.
- Tissot, SA (1770). Treaty of epilepsy, making the third volume of the treaty of the nerves and their diseases. Paris.
- Tulving, E. (1983). *Elements of episodic memory*. New York: Oxford University Press.
- Tulving, E. (1985). Memory and consciousness. *Canadian Psychologist*, 26, 1–12.
- Tulving, E. (2001). Episodic memory and common sense: How fa apart? *Philosophical Transactions of Royal Society of London*, 356 , 1505-1515.
- Tulving, E. (2002). Episodic memory: From mind to brain. *Annual Review of Psychology*, 53, 1–25
- Vargha-Khadem F., Gadian D.G., & Mishkin, M. (2001). Dissociations in cognitive memory: the syndrome of developmental amnesia. *Philosophical Transaction Royal Society of London British Biological Science*, 356, 1435-1440.
- Vargha-Khadem, F., Gadian, D.G., Watkins, K.E., et al. (1997). Differential effects of early hippocampal pathology on episodic and semantic memory. *Science*, 277, 376-380.
- Williams, J. (2003). Learning and behavior in children with epilepsy. *Epilepsy & Behavior*, 4 , 107-111.
- Williams, J., Griebel, M.L., Sharp, G.B., et al. (1998). Cognition and behavior after temporal lobectomy in pediatric patients with intractable epilepsy. *Paediatric Neurology*, 19 , 189-194.
- Zix, C., Billard, C., Motte, J. (1999). Epilepsy due to mesiotemporal sclerosis in children : 10 boxes. *Archives of Pediatrics*, 6 , 398-405.