



**HAL**  
open science

## **CNS neuroblastoma, FOXR2-activated and its mimics: a relevant panel approach for work-up and accurate diagnosis of this rare neoplasm**

Arnault Tauziède-Espariat, Dominique Figarella-Branger, Alice Métais, Emmanuelle Uro-Coste, Claude-Alain Maurage, Benoît Lhermitte, Aude Aline-Fardin, Lauren Hasty, Alexandre Vasiljevic, Dan Chiforeanu, et al.

### ► To cite this version:

Arnault Tauziède-Espariat, Dominique Figarella-Branger, Alice Métais, Emmanuelle Uro-Coste, Claude-Alain Maurage, et al.. CNS neuroblastoma, FOXR2-activated and its mimics: a relevant panel approach for work-up and accurate diagnosis of this rare neoplasm. *Acta Neuropathologica Communications*, 2023, 11 (1), pp.43. 10.1186/s40478-023-01536-7 . hal-04086974

**HAL Id: hal-04086974**

**<https://u-paris.hal.science/hal-04086974v1>**

Submitted on 2 May 2023

**HAL** is a multi-disciplinary open access archive for the deposit and dissemination of scientific research documents, whether they are published or not. The documents may come from teaching and research institutions in France or abroad, or from public or private research centers.

L'archive ouverte pluridisciplinaire **HAL**, est destinée au dépôt et à la diffusion de documents scientifiques de niveau recherche, publiés ou non, émanant des établissements d'enseignement et de recherche français ou étrangers, des laboratoires publics ou privés.



Distributed under a Creative Commons Attribution 4.0 International License

LETTER TO THE EDITOR

Open Access



# CNS neuroblastoma, *FOXR2*-activated and its mimics: a relevant panel approach for work-up and accurate diagnosis of this rare neoplasm

Arnault Tauziède-Espariat<sup>1,2\*</sup>, Dominique Figarella-Branger<sup>3</sup>, Alice Métails<sup>1,2</sup>, Emmanuelle Uro-Coste<sup>4,5,6</sup>, Claude-Alain Maurage<sup>7</sup>, Benoît Lhermitte<sup>8</sup>, Aude Aline-Fardin<sup>9</sup>, Lauren Hasty<sup>1</sup>, Alexandre Vasiljevic<sup>10</sup>, Dan Chiforeanu<sup>11</sup>, Guillaume Chotard<sup>12</sup>, Homa Adle-Biasette<sup>13</sup>, Alexandra Meurgey<sup>14</sup>, Raphaël Saffroy<sup>15</sup>, Delphine Guillemot<sup>16</sup>, Gaëlle Pierron<sup>17</sup>, Philipp Sievers<sup>18,19</sup> and Pascale Varlet<sup>1,2</sup> on behalf of the RENOCLIP-LOC

The “neuroblastoma of the central nervous system” (CNS) has been referenced in the World Health Organization’s (WHO) classification of brain tumors since 1993 [2]. However, in recent years, thanks to molecular analyses, *forkhead box R2* (*FOXR2*) alterations have become associated with this tumor type and as a result, the WHO classification renamed the neoplasm “CNS neuroblastoma (NB), *FOXR2*-activated” [4, 5]. These alterations are comprised of complex structural rearrangements

for which routine testing is not easily implemented [4]. Consequently, the diagnosis is confirmed using advanced molecular techniques (Next-generation sequencing or DNA-methylation profiling) [3]. In this context, routine biomarkers for neuropathologists are needed to facilitate a NB-*FOXR2* diagnosis. The aims of this report are to present the French national RENOCLIP-LOC network’s experience diagnosing NB-*FOXR2* and to propose an alternative diagnostic approach.

\*Correspondence:

Arnault Tauziède-Espariat  
[a.tauziède-espariat@ghu-paris.fr](mailto:a.tauziède-espariat@ghu-paris.fr)

<sup>1</sup> Department of Neuropathology, GHU Paris-Psychiatrie et Neurosciences, Sainte-Anne Hospital, 1, rue Cabanis, 75014 Paris, France

<sup>2</sup> INSERM, UMR 1266, IMA-Brain, Institut de Psychiatrie et Neurosciences de Paris, Paris, France

<sup>3</sup> Department of Anatomopathology and Neuropathology, CNRS, INP, Inst Neurophysiopathol, and APHP, La Timone Hospital, Aix-Marseille Univ, 13385 Marseille, France

<sup>4</sup> Department of Pathology, Toulouse University Hospital, Toulouse, France  
<sup>5</sup> Cancer Research Center of Toulouse (CRCT), INSERM U1037, Toulouse, France

<sup>6</sup> Université Paul Sabatier, Toulouse III, Toulouse, France

<sup>7</sup> Institute of Pathology, Centre de Biologie Pathologie, Lille University Hospital, 59000 Lille, France

<sup>8</sup> Department of Pathology, Strasbourg Hospital, Strasbourg, France

<sup>9</sup> Department of Pathology, Fort-de-France Hospital, Fort-de-France, France

<sup>10</sup> Department of Pathology and Neuropathology, GHE, Hospices Civils de Lyon, Lyon, France

<sup>11</sup> Department of Pathology, Ponchaillou Hospital, Rennes, France

<sup>12</sup> Department of Pathology, Pellegrin Hospital, Bordeaux, France

<sup>13</sup> Department of Pathology, Lariboisière Hospital, APHP, 75475 Paris, France

<sup>14</sup> Department of Biopathology, Léon Bérard Cancer Center, Lyon, France

<sup>15</sup> Department of Biochemistry and Oncogenetics, Paul Brousse Hospital, 94804 Villejuif, France

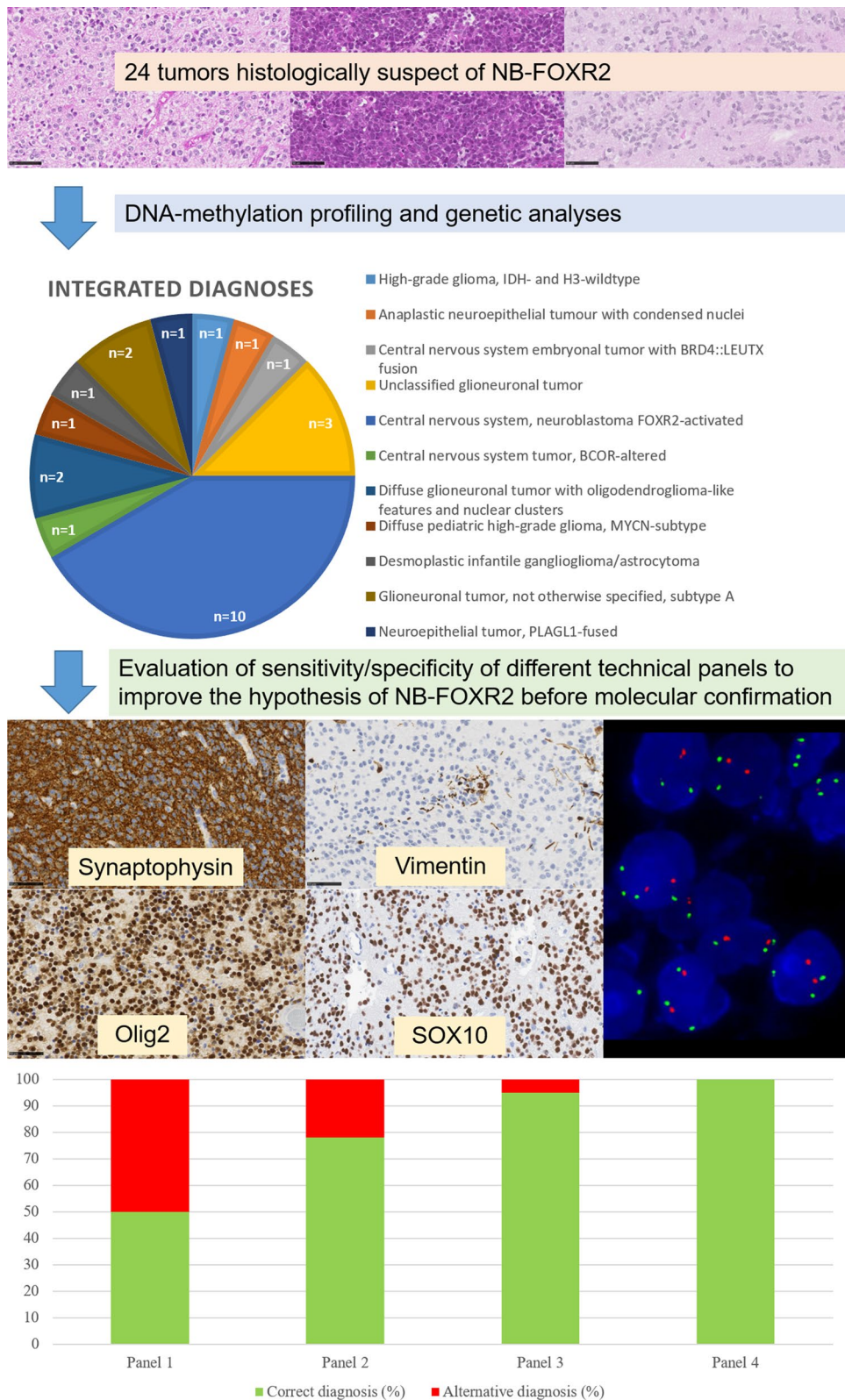
<sup>16</sup> Curie Institute Research Center, INSERMU830, Paris-Sciences-Lettres, Paris, France

<sup>17</sup> Laboratory of Somatic Genetics, Curie Institute Hospital, Paris, France

<sup>18</sup> Department of Neuropathology, Institute of Pathology, University Hospital Heidelberg, Heidelberg, Germany

<sup>19</sup> Clinical Cooperation Unit Neuropathology, German Consortium for Translational Cancer Research (DKTK), German Cancer Research Center DKFZ, Heidelberg, Germany





**Fig. 1** Flowchart of the study. Different technical panels used: panel 1 (Olig2 and synaptophysin immunopositivities, and vimentin negativity); panel 2 (Olig2, synaptophysin and SOX10 immunopositivities); panel 3 (Olig2, synaptophysin and SOX10 immunopositivities, and vimentin negativity); panel 4 (Olig2, synaptophysin and SOX10 immunopositivities, and vimentin negativity, and 1q gain). The sensitivity and specificity for each panel were: 100 and 71% (panel 1); 100 and 50% (panel 2); 100 and 86% (panel 3); and 100 and 100% (panel 4)

Our study included a total of 24 cases initially suspected to be NB-FOXR2, based on histopathology alone, and reviewed by the French national network. All tumors were pediatric (except one in a young adult) and located in the supratentorial region. We performed an immunohistochemical (IHC) panel (including Olig2, synaptophysin, vimentin, and SOX10), fluorescent in situ (FISH) analysis of chromosome 1, and DNA-methylation profiling for all tumors. Each maintained BRG1 and INI1 expression and showed no immunoreactivity for Lin28A.

DNA-methylation profiling using the CNS tumor Classifier supported the NB-FOXR2 diagnosis in 9/24 cases (37%), with a calibrated score (>0.9) for nine of the samples. The other diagnoses having scores >0.9 included: high-grade gliomas, *IDH*- and H3-wildtype (n=2); glioneuronal tumors not otherwise specified, subtype A (n=2); a diffuse glioneuronal tumor with oligodendroglioma-like features and nuclear clusters (DGONC); an anaplastic neuroepithelial tumor with condensed nuclei (ANTCON) [1]; a CNS embryonal tumor with *BRD4::LEUTX* fusion; a CNS tumor *BCOR*-altered; and a neuroepithelial tumor, *PLAGL1*-fused. An orthogonal validation, using different molecular techniques, confirmed these diagnoses (cf. Additional file 1: Table 1). The six remaining cases presented a low calibrated score for different methylation classes. All cases were included in a t-distributed stochastic neighbor embedding analysis to better characterize tumors with low scores. Finally, 10/24 cases were confirmed as NB-FOXR2.

From these results, we tested the sensitivity/specificity of different technical approaches using IHC, FISH, or combinations of these different techniques. The best diagnostic panel included an IHC panel (showing Olig2, synaptophysin, and SOX10 immunopositivities without vimentin immunoreactivity), and FISH analysis (presence of 1q gain) with a very high sensitivity/specificity (Fig. 1 and Additional file 2: Figure 1).

In accordance with the WHO Classification, our work evidenced that a diagnosis of NB-FOXR2 based on morphology alone is currently not possible. Indeed, many differential heterogeneous diagnostic pitfalls exist, including glial, glioneuronal, embryonal and new emerging tumor types. Many of these have been very recently described in the literature and are not yet listed in the latest WHO classification, highlighting the velocity with which CNS tumors are being deciphered in recent years thanks to DNA-methylation profiling, and thus, their increasing complexity. The essential diagnostic criteria of the WHO classification defines NB-FOXR2 as an embryonal tumor having foci of neuroblastic or neuronal differentiation and a *FOXR2* activation or a DNA-methylation profile aligned with this diagnosis. These genetic or epigenetic

diagnostic techniques are not routinely used or available in all countries worldwide. However, IHC and FISH analyses are well established, can be automated, are relatively easy to standardize, are less expensive, and are widely available in most pathology laboratories worldwide. In this context, the national French histopathological network's experience showed that IHC (confirming the necessity of a co-expression of Olig2 and synaptophysin, and the interest of SOX10 immunopositivity) and FISH analyses (confirming the necessity of chromosome 1q gain) may improve the diagnosis of NB-FOXR2, and help eliminate potential mimickers [3, 4].

In conclusion, the diagnosis of NB-FOXR2 may be ameliorated by using an algorithmic approach that includes several criteria based on histopathology, IHC and FISH analysis. This diagnostic panel can be tested in further series in order to be validated as a working formula that facilitates the diagnostic approach and reaches an accurate diagnosis in a resource-limited environment.

## Supplementary Information

The online version contains supplementary material available at <https://doi.org/10.1186/s40478-023-01536-7>.

**Additional file 1.** Histopathological and molecular features of differential diagnoses of CNS neuroblastoma, *FOXR2*-activated.

**Additional file 2: Figure 1.** Immunohistochemical and FISH analyses results of the differential diagnoses.

## Author contributions

ATE, and PV conducted the neuropathological examinations; ATE, PS, EUC, RS, GP, DG, and AM conducted the molecular analyses; ATE, and PV drafted the manuscript. All authors read and approved the final manuscript.

## Funding

No funding.

## Declarations

### Ethics approval and consent to participate

This study was approved by the GHU Paris Psychiatry and Neurosciences, Sainte-Anne Hospital's local ethic committee.

### Competing interests

The authors declare that they have no conflict of interest directly related to the topic of this article.

Received: 27 January 2023 Accepted: 25 February 2023

Published online: 14 March 2023

## References

- Jones D, Ismer B, Schimpf D, Reuss D, Stichel D, Casalini B, Schittenhelm J, Frank S, Boldt H, Winther-Kristensen B, Sehested AM, Scheie D, Korshunov A, Ecker J, Milde T, Pajtler K, Herold-Mende C, Witt O, Wick W, Pfister SM, von Deimling A, Sahm F (2019) Gene-12. Anaplastic neuroepithelial tumor with condensed nuclei (ANTCON): a novel brain tumor entity with recurrent NTRK fusion. *Neuro-Oncol* 21:ii83. <https://doi.org/10.1093/neuonc/noz036.083>

2. Kleihues P, Burger PC, Scheithauer BW (1993) Histological typing of tumours of the central nervous system, 2nd edn. Springer, Berlin
3. Korshunov A, Okonechnikov K, Schmitt-Hoffner F, Ryzhova M, Sahm F, Stichel D, Schrimpf D, Reuss DE, Sievers P, Suwala AK, Kumirova E, Zheludkova O, Golanov A, Jones DTW, Pfister SM, Kool M, von Deimling A (2021) Molecular analysis of pediatric CNS-PNET revealed nosologic heterogeneity and potent diagnostic markers for CNS neuroblastoma with FOXR2-activation. *Acta Neuropathol Commun* 9:20. <https://doi.org/10.1186/s40478-021-01118-5>
4. Sturm D, Orr BA, Toprak UH, Hovestadt V, Jones DTW, Capper D, Sill M, Buchhalter I, Northcott PA, Leis I, Ryzhova M, Koelsche C, Pfaff E, Allen SJ, Balasubramanian G, Worst BC, Pajtler KW, Brabetz S, Johann PD, Sahm F, Reimand J, Mackay A, Carvalho DM, Remke M, Phillips JJ, Perry A, Cowdrey C, Drissi R, Fouladi M, Giangaspero F, Łastowska M, Grajkowska W, Scheurlen W, Pietsch T, Hagel C, Gojo J, Löttsch D, Berger W, Slavc I, Haberler C, Jouvet A, Holm S, Hofer S, Prinz M, Keohane C, Fried I, Mawrin C, Scheie D, Mobley BC, Schniederjan MJ, Santi M, Buccoliero AM, Dahiya S, Kramm CM, von Bueren AO, von Hoff K, Rutkowski S, Herold-Mende C, Frühwald MC, Milde T, Hasselblatt M, Wesseling P, Rößler J, Schüller U, Ebinger M, Schittenhelm J, Frank S, Grobholz R, Vajtai I, Hans V, Schneppenheim R, Zitterbart K, Collins VP, Aronica E, Varlet P, Puget S, Dufour C, Grill J, Figarella-Branger D, Wolter M, Schuhmann MU, Shalaby T, Grotzer M, van Meter T, Monoranu C-M, Felsberg J, Reifenberger G, Snuderl M, Forrester LA, Koster J, Versteeg R, Volckmann R, van Sluis P, Wolf S, Mikkelsen T, Gajjar A, Aldape K, Moore AS, Taylor MD, Jones C, Jabado N, Karajannis MA, Eils R, Schlesner M, Lichter P, von Deimling A, Pfister SM, Ellison DW, Korshunov A, Kool M (2016) New brain tumor entities emerge from molecular classification of CNS-PNETs. *Cell* 164:1060–1072. <https://doi.org/10.1016/j.cell.2016.01.015>
5. Wesseling P, Haberler C, Huang A, Kool M, Korshunov A, Sturm D, von Hoff K (2021) CNS neuroblastoma, FOXR2-activated. In: *Central Nervous System Tumours*, 5th edn. WHO classification of tumour series, Lyon (France), pp 232–234

## Publisher's Note

Springer Nature remains neutral with regard to jurisdictional claims in published maps and institutional affiliations.

Ready to submit your research? Choose BMC and benefit from:

- fast, convenient online submission
- thorough peer review by experienced researchers in your field
- rapid publication on acceptance
- support for research data, including large and complex data types
- gold Open Access which fosters wider collaboration and increased citations
- maximum visibility for your research: over 100M website views per year

At BMC, research is always in progress.

Learn more [biomedcentral.com/submissions](https://biomedcentral.com/submissions)

