



HAL
open science

Extracorporeal membrane oxygenation (ECMO) during aplasia: A bridge towards myopericarditis recovery after autologous hematopoietic stem cell transplant for systemic sclerosis and recent Coronaravirus disease (COVID-19) vaccination

Carlotta Cacciatore, Mathilde Baudet, Estelle Jean, Simona Presente, Marylou Para, Romain Sonnevile, Dimitri Arangalage, Nassim Ait Abdallah, Flore Sicre de Fontbrune, Pedro Henrique Prata, et al.

► To cite this version:

Carlotta Cacciatore, Mathilde Baudet, Estelle Jean, Simona Presente, Marylou Para, et al.. Extracorporeal membrane oxygenation (ECMO) during aplasia: A bridge towards myopericarditis recovery after autologous hematopoietic stem cell transplant for systemic sclerosis and recent Coronaravirus disease (COVID-19) vaccination. *Current Research in Translational Medicine*, 2024, 72 (3), pp.103449. 10.1016/j.retram.2024.103449 . hal-04598763

HAL Id: hal-04598763

<https://u-paris.hal.science/hal-04598763>

Submitted on 3 Jun 2024

HAL is a multi-disciplinary open access archive for the deposit and dissemination of scientific research documents, whether they are published or not. The documents may come from teaching and research institutions in France or abroad, or from public or private research centers.

L'archive ouverte pluridisciplinaire **HAL**, est destinée au dépôt et à la diffusion de documents scientifiques de niveau recherche, publiés ou non, émanant des établissements d'enseignement et de recherche français ou étrangers, des laboratoires publics ou privés.



Distributed under a Creative Commons Attribution - NonCommercial - NoDerivatives 4.0 International License

Contents lists available at [ScienceDirect](https://www.sciencedirect.com)

Current Research in Translational Medicine

journal homepage: www.elsevier.com/locate/retram

Brief communication

Extracorporeal membrane oxygenation (ECMO) during aplasia: A bridge towards myopericarditis recovery after autologous hematopoietic stem cell transplant for systemic sclerosis and recent Coronaravirus disease (COVID-19) vaccination



Carlotta Cacciatore^{a,b}, Mathilde Baudet^c, Estelle Jean^{d,e}, Simona Presente^f, Marylou Para^{g,h}, Romain Sonnevile^{g,h}, Dimitri Arangalageⁱ, Nassim Ait Abdallah^j, Flore Sicre de Fontbrune^k, Pedro Henrique Prata^k, Benjamin Crichi^l, Baptiste Hervier^l, Nathalie Parquet^m, Gilles Soulatⁿ, Elie Mousseauxⁿ, Richard K Burt^{o,p}, Dominique Farge^{a,b,q,*}

^a Unité de Médecine Interne (UF04): CRMR MATHEC, Maladies Auto-immunes et Thérapie Cellulaire, Centre de Référence des Maladies auto-immunes systémiques Rares d'Ile-de-France, AP-HP, Hôpital St-Louis, F-75010 Paris, France

^b Université Paris Cité, IRSL, Recherche Clinique en hématologie, immunologie et transplantation, URP3518, F-75010 Paris, France

^c Department of Cardiology, Hospital Saint-Louis, Paris, France

^d Département de Médecine Interne, Hôpital de la Timone, Assistance Publique des Hôpitaux de Marseille, Marseille, France

^e Centre de référence des syndromes drépanocytaires majeurs, thalassémies et autres pathologies rares du globule rouge et de l'érythrocytose, Assistance Publique des Hôpitaux de Marseille, 264, rue Saint-Pierre, 13005 Marseille, France

^f Medical and Infectious Diseases ICU, APHP, Bichat Hospital, Paris, France

^g Department of Cardiovascular Surgery and Transplantation, Bichat Hospital, AP-HP, Paris, France

^h Laboratory of Vascular Translational Science, University of Paris-Cité, UMR 1148 Paris, France

ⁱ Cardiology Department, AP-HP, Bichat Hospital and Université de Paris-Cité, Paris, France

^j Service de Médecine Interne 2, maladies auto-immunes et systémiques, AP-HP, Hôpital Pitié-Salpêtrière, Paris, France

^k Hematology and Transplantation Department, Saint Louis Hospital, Paris, France

^l Unité de Médecine interne (UF07), AP-HP, Hôpital St-Louis, F-75010 Paris, France

^m Unité d'Aphérèse Thérapeutique, Hôpital Saint-Louis, AP-HP, Paris, France

ⁿ Radiologie, Hôpital Européen Georges Pompidou, APHP, INSERM 970, Université de Paris-Cité, France

^o Scripps Health, La Jolla USA,

^p Genani Corporation, Chicago, USA

^q Department of Medicine, McGill University, H3A 1A1, Montreal, Canada

ARTICLE INFO

Keywords:

Myocarditis
mRNA SARS-CoV-2 vaccine
Systemic sclerosis
Hematopoietic stem cell transplantation
ECMO

ABSTRACT

Systemic sclerosis (SSc) is a rare autoimmune disease (AD), characterised by early diffuse vasculopathy, activation of the immune response and progressive skin and internal organ fibrosis. In severe progressive diffuse SSc (dSSc), autologous hematopoietic stem cell transplantation (aHSCT) improves survival, despite its own risk of complications and transplant related mortality (TRM).

We present herein the case of a dSSc patient undergoing aHSCT with low dose cyclophosphamide conditioning and sudden acute myopericarditis and cardiogenic shock, four weeks after a second mRNA SARS-CoV-2 vaccine (Pfizer) injection. Four days of extracorporeal membrane oxygenation (ECMO) support during the aplasia period, allowed to observe full cardiac function recovery and progressive SSc rehabilitation with sustained disease response at 30 months follow-up. This report illustrates, for the first time to our knowledge, that ECMO can be indicated despite aplasia during aHSCT and successfully used as a bridge towards heart function recovery in highly selected and fragile AD patients. We review the factors that may contribute to endothelial and myocardial stunning and acute reversible cardiac failure in SSc and aggravate intrinsic endothelial injury during the aHSCT procedure. These classically include: cyclophosphamide drug toxicity, viral infections and autoimmune

* Corresponding author at: Unité de Médecine Interne (UF04): CRMR MATHEC, Maladies Auto-immunes et Thérapie Cellulaire, Centre de Référence des Maladies auto-immunes systémiques Rares d'Ile-de-France, AP-HP, Hôpital St-Louis, F-75010 Paris, France.

E-mail address: dominique.farge-bancel@aphp.fr (D. Farge).

<https://doi.org/10.1016/j.retram.2024.103449>

Received 14 March 2024; Accepted 8 April 2024

Available online 9 April 2024

2452-3186/© 2024 The Authors. Published by Elsevier Masson SAS. This is an open access article under the CC BY-NC-ND license (<http://creativecommons.org/licenses/by-nc-nd/4.0/>).

activation with disease flair per se. In the COVID-19 pandemic times, acute myocarditis due to recent viral infection or mRNA vaccine per se, must also be considered.

A 40 year-old female, with severe progressive diffuse systemic sclerosis (dSSc) was admitted for autologous hematopoietic stem cell transplantation (aHSCt) in August 2021. SSc had been diagnosed for two years with a modified Rodnan skin score (mRSS) at 10/51, articular plus digestive tract involvement (2013 American College of Rheumatology (ACR) / European League against rheumatism (EULAR) score at 14). At that time, patient had just delivered her second healthy child after uneventful pregnancy, as three years before. Bilateral silicone breast implants in place for five years were retrieved. She had discontinued smoking since 2018. Treatment with hydroxychloroquine, low-dose corticosteroids plus methotrexate was started and replaced after ten months by mycophenolate mofetil (MMF, 2 g/day), which also failed to halt disease progression. Patient had elevated erythrocyte sedimentation rate (33–55 mm/h; Normal < 5) and fibrinogen (5 g/L; Normal 2–4), presence of Antinuclear (titer of 1:1280), anti-RNA polymerase III (39 UI/mL) and anti-citrullinated protein (45UI/L) antibodies and rheumatoid factor (142 U/ml). Anti topo-isomerase I (Scl-70), anti-centromere, anti Beta2 glycoprotein 1, anti-cardiolipin antibodies and Lupus Anticoagulant were all negative. In April 2021, multidisciplinary team meeting (MDT) (www.mathec.com) recommended treatment by aHSCt using “cardiac safe” conditioning regimen considering increased mRSS at 30/51, weight loss above 10 % in 3 months plus abnormal Cardiac Magnetic Resonance (CMR) imaging with sub-epicardial enhancement in the inferior Left Ventricular (LV) wall, without oedema nor T1 hypersignal. Echocardiography (LV Ejection Fraction (LVEF) 65 %), standard and 24 h electrocardiograms (ECG) were all normal. Pre-aHSCt cardiac catheterization was not performed. Lung function tests were normal, with oesophageal distention and no interstitial disease on chest computed tomography (CT). Blood pressure (BP) and renal function (creatinine clearance 116 ml/min) were normal without proteinuria nor haematuria.

On May 3rd 2021, patient received a first mRNA SARS-CoV-2 vaccine (Pfizer) injection. Two weeks later, a right subclavian central venous

port-catheter (CVC) was implanted. Prednisone was increased at 15 mg per os (p.o) daily, angiotensin converting enzyme (ACE) inhibitors and anti-acids were introduced, MMF was stopped and peripheral hematopoietic stem cells (HSC) mobilization was planned a month later (Fig. 1). The day before chemotherapy for peripheral HSC mobilization, echocardiography revealed an asymptomatic CVC-related right atrial thrombus (28×14 mm diameter) with no pulmonary embolism on angiography CT scan nor additional thrombi on cardiac angiography. Low Molecular Weight Heparin (LMWH, *tinzaparin 9000 UI/day*) treatment was initiated and HSC mobilization procedure postponed for ten days. Thereafter, cyclophosphamide (CYC) (700 mg/m²/ i.v daily on two consecutive days, total dose 1.4 g/m²), followed by subcutaneous (s.c) G-CSF (filgrastim, 10 µg/kg/day) for five days allowed to collect 10.2 × 10⁶ CD34+/kg HSC using one cytopheresis. No ex-vivo graft manipulation was performed. The CVC was retrieved four days later and patient discharged with two additional months of LMWH at curative doses and same previous treatment, albeit decreased oral prednisone at 7.5 mg daily. Three weeks later, onset of skin ulcerations, severe acute polyarthritis and inflammatory syndrome related to SSc disease flair required 125 mg iv prednisolone (once), increased oral prednisone to 15 mg daily and MMF reintroduction. On July 22nd, 2021, the second dose of mRNA SARS-CoV-2 vaccine (Pfizer) was injected. Ten days later, patient was hospitalized for the aHSCt procedure, but had to remain isolated for two weeks due to COVID-19 cluster infection familial contact. She remained asymptomatic and repeated intranasal SARS-COV2 PCR were all negative. Meanwhile her unvaccinated mother, children and husband were all diagnosed positive for SARS-COV2 on real time polymerase chain reaction (PCR) swab testing.

Conditioning chemotherapy was started i.v. on August 19th 2021 using: 1 mg/kg methylprednisolone daily (from day-6 to day-1 before aHSCt), 500 mg i.v. Rituximab (day-6), Fludarabine 30 mg/m² (47 mg total dose daily) for four days (from day-5 to day-2), rabbit anti-thymocyte globulins (ATG 6 mg/kg total dose) for five days (from

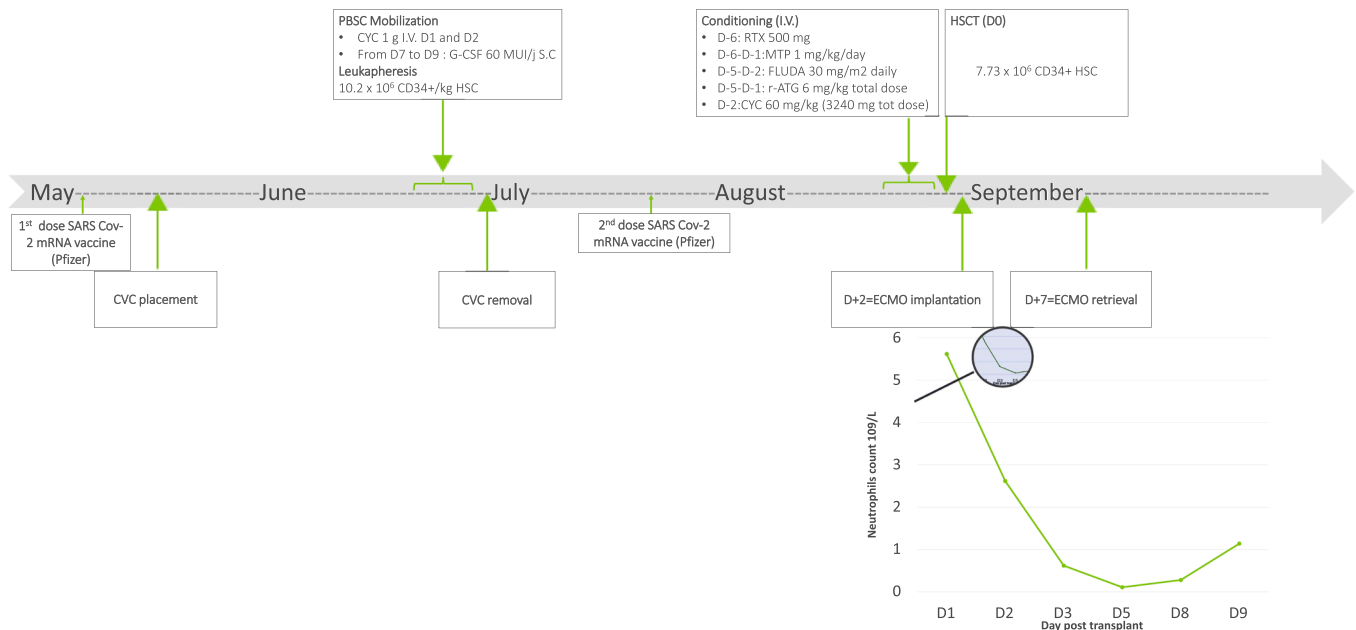


Fig. 1. Time line of treatment process for autologous Hematopoietic Stem Cell Transplantation.

PBSC, Peripheral Blood Stem Cells; CVC, Central Venous Catheter; HSC, Hematopoietic Stem Cells; CYC, cyclophosphamide; G-CSF, Granulocyte-Colony Stimulating Factor (*Filgrastim*); RTX, rituximab (anti-CD20); MTP, methylprednisolone; FLUDA, fludarabine; r-ATG, rabbit anti thymocyte globulin; ECMO, Extra Corporeal Membrane Oxygenation.

day-5 to day-1, at respectively 0.5, 1, 1.5, 1.5, 1.5 mg/kg daily) and 3.240 g total dose CYC (day-2) with sustained hyperhydration (3000 ml/m²) since day-5. On day-2, after CYC administration, patient suffered transient respiratory discomfort while oxygen saturation, ECG and troponin levels remained normal. On Day 0 for aHSCT, intermittent retrosternal chest pain, shortness of breath with sinus tachycardia (140 beats per minute) plus ST-elevation on ECG lateral leads were diagnosed. Echocardiography revealed mild left ventricular dysfunction with a 45 % LVEF, normal pulmonary artery pressure without pericardial effusion. Blood high sensitivity troponin (Hs-Tropo) levels rose from 30 to 48 ng/L (normal 0–14 ng/L) within 3 h and C N-terminal pro-B-type natriuretic peptide (pro-BNP) level was 3820 ng/L (normal 0–300). A diagnosis of clinically suspected myocarditis was established

[1] and daily repeated clinical, ECG, cardiac enzymes and echocardiography were monitored. A total of 7.73×10^6 CD34+/kg HSC cells were administered.

On day+1 post-aHSCT, thoracic pain and dyspnoea worsened with transient hypotension and peripheral vasoconstriction responsive to volume expansion. Repeated ECG and echocardiography were similar, with normal renal and hepatic functions. The second dose of Rituximab was cancelled and empiric treatment by iv piperacillin/tazobactam was started. From day+1 to day+2, cardiovascular symptoms worsened with increased Hs-Tropo (619 µg/L) and pro-BNP (31,577 ng/L) levels, hyperlactatemia (2.6 mmol/L) without acidosis. Patient was transferred to the intensive care unit (ICU) and noradrenaline i.v. was started. Consecutive echocardiography found a LVEF at 20 % and then at 15 %

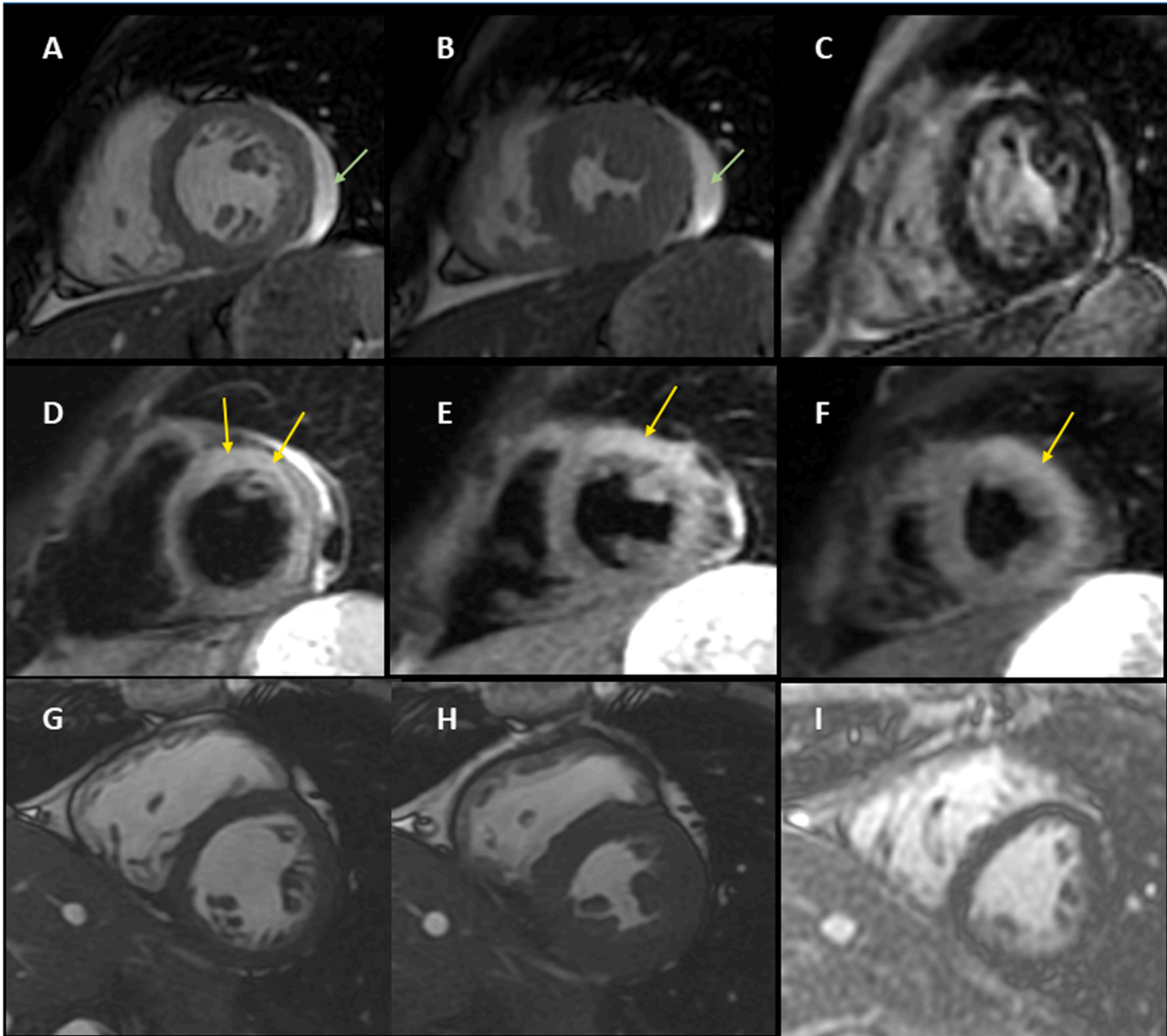


Fig. 2. Evolution of Cardiac Magnetic Resonance (CMR) 1.5 T imaging obtained at 13 days (A,B,C,D,E,F) and 6 months (G,H,I) after autologous Hematopoietic Stem Cell Transplantation.

LVEF: left ventricular (LV) ejection fraction (EF).

At Day 13 after aHSCT, the end-diastolic (A) and end-systolic (B) cine steady-state free precession MRI (SSFP) images reveal normal LVEF (62 %) and absence of late gadolinium enhancement (C), with severe oedema (yellow arrows) in the LV anterior and lateral walls on the basal (D), middle (E) and apical (F) small-axis, heavily T2-weighted images. Native T1 images were nearly normal in the septum (1046 ms) and at 1150 ms in the LV walls with oedema. Circumferential pericardial effusion is clearly visible in A and B (green arrows).

At six months after aHSCT, the oedema had disappeared and T2 weighted SSFP images were normal. The end-diastolic (G) and end-systolic (H) images still confirm a normal LVEF, with no late enhancement (I). Native T1 values in the anterior LV wall (991 ms) and in the septum (972 ms) and respective extracellular volume values (29 % and 28 %) had returned to normal. The initial circumferential pericardial effusion (green arrows A and C), has disappeared (G and H).

with severe right ventricular dysfunction, plus non-compressive, moderate (7 mm) left and right posterior ventricular pericardial effusion. Considering sustained cardiogenic shock for 48 h with severe global hypokinesia, early encephalopathy symptoms in the absence of pulmonary, renal or hepatic failure, MDT validated the use of blood ECMO support. On day+2 post-aHSCT, the ECMO cannulae were percutaneously inserted under local anaesthesia, in the right femoral artery and the left femoral vein for blood return, and flow was started at 3 L/min. On day+3, she became thrombocytopenic and neutropenic, prompting 30 UI/day G-CSF treatment. Patient remained in aplasia and on ECMO for four days. On day+5 post-aHSCT, heart failure was sustained with tachycardia at 150/min, 20 % LVEF and moderate circumferential non-compressive (14 to 20 mm) pericardial effusion, plus moderate acute kidney injury (KDIGO 1) [2] without invasive mechanical ventilation. On day+6 post-aHSCT, neurological, cardiac and renal function recovery signs appeared, LVEF increased from 30 to 55 %, allowing to decrease noradrenaline at 2 mg/h and ECMO flow to 2 L/min. On day+7 post-aHSCT, once weaned from vasopressors, the ECMO canulae were surgically removed and use of Fogarty arterial embolectomy catheter retrieved significant amount of inflammatory thrombi. On day+9 post-aHSCT, normal neutrophils count (1650/mm³) allowed to stop G-CSF. Venous access was maintained via a left external jugular vein catheter. All repeated viral tests were negative: PCR testing in swab for SARS-CoV2; PCR testing in blood for SARS-CoV2, Parvovirus B19, Cytomegalovirus (CMV), Human T-lymphotropic virus, adenovirus, enterovirus, BK virus, Epstein Barr Virus, Varicella Zona Virus, Herpes Simplex Virus 1 and 2, Human Herpes Virus 6 (HHV-6) and serological tests for SARS-CoV2, Hepatitis A, B, C, D and E and human immunodeficiency virus. On day+13 post-aHSCT, 1.5 T CMR showed diffuse and heterogeneous acute myocarditis profile according to the 2018 Lake Louise Criteria [3] (Fig. 2, A to F). Cardiac CT scan 24 h later appeared normal.

On day+16 post-aHSCT, the CMV blood-PCR had increased to 4.09 log versus 3.76 log 5 days earlier and CMV reactivation treatment was initiated by i.v ganciclovir (5 mg/kg twice daily for 21 days). The SARS-CoV2 Ig-anti N serum antibodies remained negative, while spike-protein (anti-S) antibodies, that were negative (21.9UA/ml) three weeks before, had become positive (137 UA /ml; threshold > 55 UA /ml). An extended deep vein thrombosis (DVT) of the left external iliac and common femoral veins until the intrahepatic inferior vena cava was diagnosed at site of the ECMO venous canula implantation. BP (90/50mm Hg), Heart Rate (76 per min) were stable, with normalized blood Hs-Tropo and pro-BNP levels. Patient remained under prednisone 5 mg daily, bisoprolol (1.25 mg daily), ramipril (1.25 mg daily), sulfamethoxazole-trimethoprim (400/800 mg daily), amoxicilline (500 mg x 2 daily), valaciclovir (1000 mg daily), Tinzaparine 10 000 UI sc daily and antireflux plus antiproton inhibitors and discharged. Six months post- aHSCT, clinical examination showed mRSS at 8/51, normal cardiopulmonary clinical examination with sustained CD4 lymphopenia (300/mm³), 800 CD8/mm³ and 200 CD19/mm³. Standard and 24 h Holter ECG, cardiac echography and CMR were all back to normal (Fig. 2, G to I) with resolution regression of left auricular thrombus on cardiac CT scan and inferior vena cava thrombus. At 12 months immune reconstitution was completed with stable mRSS, normal lung function and full recovery of cardiac function (standard and 24 h ECG, echocardiography, CMR) were all sustained 24 and 30 months after aHSCT.

Discussion

Cardiac and pulmonary involvement are the leading causes of death in SSc [4]. In rapidly progressive dSSC patients, where spontaneous three to five years survival varies between 30 and 50%, three randomized trials (ASSIST, ASTIS, SCOT) showed that aHSCT improves survival until at least five to seven years [5]. Over the years, the aHSCT procedure safety profile raised progressively with better identification of

treatment and/or patient-related risk factors, that require specific cardiopulmonary assessment and the use of "cardiac safe » conditioning regimen in SSc fragile patients [6]. Today, aHSCT for severe dSSc is indicated with a grade I level of evidence [7], although it still carries its own risk of toxicity, with a Transplant Related Mortality (TRM) around 3 to 6 %.

Endothelial cell (EC) injury that leads to microcirculatory dysfunction, widespread vasculopathy and loss of capillaries with chronic tissue ischemia is an early and central event in SSc. As described forty years ago [8], the most striking abnormalities occur in small arteries and arterioles, where distinctive intimal proliferation of cells, are thought to originate from medial smooth muscle and concentrically arranged in a matrix of ground substance. The coagulation cascade may also be triggered by intima lesions, leading to fibrin deposition, reduced blood flow and local ischemia. Subsequent healing of the vascular walls with proliferative vascular response and luminal narrowing also account for abnormal functional and structural responses to any other cause of repeated vascular insults, each of which being able to induce additional acute and chronic endothelial injury. In the present case, "definite" acute myo(pericarditis) was diagnosed based on clinical symptoms, ECG, abnormal troponin concentrations and CMR [3]. Several factors, alone or combined, were successively considered as potential triggers aggravating SSc cardiac involvement, as diagnosed on the first CMR before the procedure. These include: viral infections, including COVID-19 and the risk associated with vaccine per se, SSc disease flares and autoimmune activation and CYC drug toxicity.

Indeed, viral infections are classically recognized as the most frequent causes of acute or subacute myocarditis, mainly related to Coxsackie or Parvovirus B19 viruses [9], while enterovirus, adenovirus, HHV6 or CMV infections are also occasionally reported in transplant recipients. In the pandemic times, COVID-19 was also at the forefront of viral causes. Establishing the diagnosis of virus-related myocarditis is challenging and immunocompromised hosts are more likely to develop an organ specific disease. Here, all viral PCR were negative at time of acute myocarditis and endomyocardial biopsy (EMB) was impossible to perform during aplasia. CMV reactivation was diagnosed on day+16 after aHSCT, once patient had been discharged from the ICU and the primary diagnosis of viral infection related myocarditis was not confirmed. Covid-19 infection was ruled out after 2 weeks of isolation despite contact, but the role of recent COVID-19 vaccination in a fragile SSc patient was highly likely, as a trigger for all events, including for the onset of CVC-related thrombosis after the first vaccine injection and for the acute myocarditis which occurred 3 weeks after the 2nd vaccine injection. In addition, although post ECMO extended thrombosis is frequent, here the thrombus was also due or contributed in part by COVID vaccine, as it was associated with an increase in spike-protein (anti-S) antibodies. In fragile patients adequate vaccination, using Pfizer or Moderna vaccines with at least two injections, is one of the safest and most effective prophylactic measures, in addition to proper use of personal protection equipment and avoidance of contamination exposure [10]. The French health authorities recommended to perform the *ad hoc* vaccination in SSc patients at risk for a severe SARS-CoV-2 infection course due to underlying interstitial lung disease and/or immunosuppression as soon as available on January 1st, 2021. Thereafter, the ADWP-EBMT guidelines recommended vaccination against SARS-CoV2, as early as 3 months after aHSCT for autoimmune diseases and did not specify the minimum delay prior to the mobilization and aHSCT procedures [10]. While gaining knowledge on the Covid-19 vaccine effects, association between the development of myocarditis and the receipt of mRNA vaccines was progressively reported [11–13]. Significant clustering of these events within the first week after vaccination, and more frequently after the second dose, provides additional evidence of an association between mRNA vaccines and myocarditis / pericarditis in younger male recipients [14]. One may argue that temporal association does not prove, but only suggests that the vaccine is the cause. In the present case, while the first vaccine injection may have

triggered the unusual CVC related thrombosis, the second vaccine injection was performed three weeks after the mobilisation procedure, whereas patient already suffered from SSc disease flair, possibly favoured by the use of G-CSF for mobilisation and / or by the mRNA vaccine first injection.

CY induced toxicity and cardiac dysfunction are usually dose dependent. Here we used a cardiac safe conditioning regimen [6], as recommended for SSc patient with abnormal CMR cardiac before transplant. It is therefore unlikely that the CY dose accounted for the observed acute myocarditis. CY systemic hypersensitivity, an inflammatory disease of the myocardium which is not dose dependent, may exceptionally occur [15]. Clinical manifestations may be nonspecific, with a diagnosis seldom established later in time. Immuno-allergic CY toxicity was also considered, since CMR described a heterogeneous diffuse infiltrative pattern atypical for viral myocarditis, and here it cannot be totally ruled out in the absence of EMB. The relationship between micronutrient deficiency and myocardial disease is already described in SSc [16], but all Vitamin D and B1 (thiamine), Iron, Magnesium, Selenium and Zinc plasma levels were normal. Altogether, the role of Covid-19 vaccine is retrospectively highly likely in the sudden onset of subacute myocarditis, either as a trigger or an aggravating factor.

Importantly cardiac stunning and myocardial injury can be transient, despite acute severe myo(pericarditis). Here, the use of inotropic and ECMO mechanical support despite aplasia allowed to achieve a bridge toward cardiac recovery. ECMO is a rescue technique that can be used temporarily to replace the heart and/or lung functions of the most severe patients [17]. It may serve as a bridge to-recovery or to-organ transplantation for patients with treatment-refractory heart and/or lung failure(s). Recent international expert statement addressed the difficult questions raised by the use of ECMO in allogeneic or autologous HSCT recipients, considering their very poor outcome but also the importance of individual case analysis, and the ethical dilemma in the absence of prior clinical evidence for efficacy of the procedure [18]. Combined advances in the field of HSCT and in the management of these highly fragile patients allowed to improve their ICU survival from 44 % to 60 % over the past 20 years [17,18] with renewed interest in advanced life support therapies, such as ECMO, for refractory respiratory or cardiac failure in carefully selected patients. Early recognition of potential rescue therapy candidates could be critical to provide appropriate care.

Conclusions

To the best of our knowledge, this is the first case report in the literature of potentially COVID vaccine hypersensitivity myocarditis and cardiogenic shock who survived to ECMO during aplasia after aHSCT. The present observation led us to change our practices and to highlight the importance of completing all vaccination program at least 3 months before the HCS mobilization procedure. An alternative is to recommend vaccination 6 months after aHSCT when patients can mount an immune response and to give one dose of Immunoglobulins iv on day of aHSCT discharge so as to provide antibodies immunity in the mean time.

Acknowledgments

We thank Pr A Jacquier (Marseille) for review assessment of CMR evaluation before the mobilization procedure.

References

- [1] Basso C. Myocarditis. *N Engl J Med* 2022;387:1488–500. <https://doi.org/10.1056/NEJMr2114478>.
- [2] Khwaja A. KDIGO clinical practice guidelines for acute kidney injury. *Nephron Clin Pract* 2012;120:c179–84. <https://doi.org/10.1159/000339789>.
- [3] Ferreira VM, Schulz-Menger J, Holmvang G, Kramer CM, Carbone I, Sechtem U, et al. Cardiovascular magnetic resonance in nonischemic myocardial inflammation: expert recommendations. *J Am Coll Cardiol* 2018;72:3158–76. <https://doi.org/10.1016/j.jacc.2018.09.072>.
- [4] Elhai M, Meune C, Boubaya M, Avouac J, Hachulla E, Balbir-Gurman A, et al. Mapping and predicting mortality from systemic sclerosis. *Ann Rheum Dis* 2017; 76:1897–905. <https://doi.org/10.1136/annrheumdis-2017-211448>.
- [5] Burt RK, Farge D. Autologous HSCT is efficacious, but can we make it safer? *Nat Rev Rheumatol* 2018;14:189–91. <https://doi.org/10.1038/nrrheum.2018.34>.
- [6] Burt RK, Han X, Quigley K, Arnavotic I, Shah SJ, Lee DC, et al. Cardiac safe hematopoietic stem cell transplantation for systemic sclerosis with poor cardiac function: a pilot safety study that decreases neutropenic interval to 5 days. *Bone Marrow Transplant* 2020. <https://doi.org/10.1038/s41409-020-0978-2>.
- [7] Snowden JA, Sánchez-Ortega I, Corbacioglu S, Basak GW, Chabannon C, de la Camara R, et al. Indications for haematopoietic cell transplantation for haematological diseases, solid tumours and immune disorders: current practice in Europe, 2022. *Bone Marrow Transplant* 2022;57:1217–39. <https://doi.org/10.1038/s41409-022-01691-w>.
- [8] Kahaleh MB, Sherer GK, LeRoy EC. Endothelial injury in scleroderma. *J Exp Med* 1979;149:1326–35. <https://doi.org/10.1084/jem.149.6.1326>.
- [9] Olejniczak M, Schwartz M, Webber E, Shaffer A, Perry TE. Viral myocarditis-incidence, diagnosis and management. *J Cardiothorac Vasc Anesth* 2020;34: 1591–601. <https://doi.org/10.1053/j.jvca.2019.12.052>.
- [10] Greco R, Alexander T, Burman J, Del Papa N, de Vries-Bouwstra J, Farge D, et al. Hematopoietic stem cell transplantation for autoimmune diseases in the time of COVID-19: EBMT guidelines and recommendations. *Bone Marrow Transplant* 2021;56:1493–508. <https://doi.org/10.1038/s41409-021-01326-6>.
- [11] Marschner CA, Shaw KE, Tijmes FS, Fronza M, Khullar S, Seidman MA, et al. Myocarditis following COVID-19 vaccination. *Heart Fail Clin* 2023;19:251–64. <https://doi.org/10.1016/j.hfc.2022.08.012>.
- [12] Lee ASY, Balakrishnan IDD, Khoo CY, Ng CT, Loh JKK, Chan LL, et al. Myocarditis following COVID-19 vaccination: a systematic review (October 2020–October 2021). *Heart Lung Circ* 2022;31:757–65. <https://doi.org/10.1016/j.hlc.2022.02.002>.
- [13] Klein NP, Lewis N, Goddard K, Fireman B, Zerbo O, Hanson KE, et al. Surveillance for adverse events after COVID-19 mRNA vaccination. *JAMA* 2021;326:1390–9. <https://doi.org/10.1001/jama.2021.15072>.
- [14] Mevorach D, Anis E, Cedar N, Bromberg M, Haas EJ, Nadir E, et al. Myocarditis after BNT162b2 mRNA vaccine against Covid-19 in Israel. *New Engl J Med* 2021; 385:2140–9. <https://doi.org/10.1056/NEJMoa2109730>.
- [15] Martin M, Fornecker L, Marcellin L, Mousseaux E, Hij A, Snowden JA, et al. Acute and fatal cardiotoxicity following high-dose cyclophosphamide in a patient undergoing autologous stem cell transplantation for systemic sclerosis despite satisfactory cardiopulmonary screening. *Bone Marrow Transplant* 2017;52: 1674–7. <https://doi.org/10.1038/bmt.2017.188>.
- [16] Dupont R, Longué M, Galinier A, Cinq Frais C, Ingueneau C, Astudillo L, et al. Impact of micronutrient deficiency & malnutrition in systemic sclerosis: cohort study and literature review. *Autoimmun Rev* 2018;17:1081–9. <https://doi.org/10.1016/j.autrev.2018.05.010>.
- [17] Rajsic S, Tremblay B, Jadzic D, Breitkopf R, Oberleitner C, Popovic Krneta M, et al. Extracorporeal membrane oxygenation for cardiogenic shock: a meta-analysis of mortality and complications. *Ann Intensive Care* 2022;12:93. <https://doi.org/10.1186/s13613-022-01067-9>.
- [18] Di Nardo M, MacLaren G, Schellongowski P, Azoulay E, DeZern AE, Gutierrez C, et al. Extracorporeal membrane oxygenation in adults receiving hematopoietic cell transplantation: an international expert statement. *Lancet Respir Med* 2023;11: 477–92. [https://doi.org/10.1016/S2213-2600\(22\)00535-5](https://doi.org/10.1016/S2213-2600(22)00535-5).