



**HAL**  
open science

## Screening for precancerous anal lesions linked to human papillomaviruses: French recommendations for clinical practice

L. Spindler, I. Etienney, L. Abramowitz, V. de Parades, F. Pigot, L. Siproudhis, J. Adam, V. Balzano, D. Bouchard, N. Bouta, et al.

### ► To cite this version:

L. Spindler, I. Etienney, L. Abramowitz, V. de Parades, F. Pigot, et al.. Screening for precancerous anal lesions linked to human papillomaviruses: French recommendations for clinical practice. *Techniques in Coloproctology*, 2024, 28 (1), pp.23. 10.1007/s10151-023-02899-8. hal-04599417

**HAL Id: hal-04599417**

**<https://u-paris.hal.science/hal-04599417v1>**

Submitted on 24 Sep 2024

**HAL** is a multi-disciplinary open access archive for the deposit and dissemination of scientific research documents, whether they are published or not. The documents may come from teaching and research institutions in France or abroad, or from public or private research centers.

L'archive ouverte pluridisciplinaire **HAL**, est destinée au dépôt et à la diffusion de documents scientifiques de niveau recherche, publiés ou non, émanant des établissements d'enseignement et de recherche français ou étrangers, des laboratoires publics ou privés.



Distributed under a Creative Commons Attribution 4.0 International License



# Screening for precancerous anal lesions linked to human papillomaviruses: French recommendations for clinical practice

L. Spindler<sup>1</sup> · I. Etienney<sup>2</sup> · L. Abramowitz<sup>3</sup> · V. de Parades<sup>1</sup> · F. Pigot<sup>4</sup> · L. Siproudhis<sup>5</sup> · J. Adam<sup>6</sup> · V. Balzano<sup>7</sup> · D. Bouchard<sup>4</sup> · N. Bouta<sup>8</sup> · M. Bucau<sup>9</sup> · A. Carlo<sup>5</sup> · J. Chanal<sup>10</sup> · C. Charpentier<sup>11</sup> · G. Clifford<sup>12</sup> · M. Draullette<sup>13</sup> · N. Fathallah<sup>1</sup> · V. Ferré<sup>11</sup> · J.-F. Fléjou<sup>14</sup> · S. Fouéré<sup>15,16</sup> · T. Higuero<sup>17</sup> · L. Kassouri<sup>1</sup> · S. Kurt<sup>1</sup> · A. Laurain<sup>3</sup> · E. Leclerc<sup>18</sup> · Q. Lepiller<sup>19</sup> · A.-C. Lesage<sup>2</sup> · D. Mège<sup>20</sup> · A. Ménard<sup>21</sup> · P. Merle<sup>8</sup> · P. Mortreux<sup>22</sup> · C. Noël<sup>23</sup> · H. Péré<sup>24,25</sup> · J.-L. Prétet<sup>26,27</sup> · D. Roland<sup>1</sup> · G. Staumont<sup>8</sup> · L. Tracanelli<sup>4</sup> · L. Vuitton<sup>28</sup> · S. Wylomanski<sup>29</sup> · O. Zaegel-Faucher<sup>30</sup> · Société Nationale Française de Colo-Proctologie

Received: 14 July 2023 / Accepted: 1 December 2023  
© The Author(s) 2024

## Abstract

In France, about 2000 new cases of anal cancer are diagnosed annually. Squamous cell carcinoma is the most common histological type, mostly occurring secondary to persistent HPV16 infection. Invasive cancer is preceded by precancerous lesions. In addition to patients with a personal history of precancerous lesions and anal cancer, three groups are at very high risk of anal cancer: (i) men who have sex with men and are living with HIV, (ii) women with a history of high-grade squamous intraepithelial lesions (HSILs) or vulvar HPV cancer, and (iii) women who received a solid organ transplant more than 10 years ago. The purpose of screening is to detect HSILs so that they can be treated, thereby reducing the risk of progression to cancer. All patients with symptoms should undergo a proctological examination including standard anoscopy. For asymptomatic patients at risk, an initial HPV16 test makes it possible to target patients at risk of HSILs likely to progress to cancer. Anal cytology is a sensitive test for HSIL detection. Its sensitivity is greater than 80% and exceeds that of proctological examination with standard anoscopy. It is indicated in the event of a positive HPV16 test. In the presence of cytological abnormalities and/or lesions and a suspicion of dysplasia on clinical examination, high-resolution anoscopy is indicated. Performance is superior to that of proctological examination with standard anoscopy. However, this technique is not widely available, which limits its use. If high-resolution anoscopy is not possible, screening by a standard proctological examination is an alternative. There is a need to develop high-resolution anoscopy and triage tests and to evaluate screening strategies.

**Keywords** HPV · Screening · Guidelines · High-resolution anoscopy · Precancerous anal lesions · HSIL

## Abbreviations

ASS	Anal self-sampling
EA	Expert agreement
hHSIL	Histological HSIL
HIV	Human immunodeficiency virus
HPV	Human papillomavirus
HRA	High-resolution anoscopy
HR-HPV	High-risk HPV
HSIL	High-grade intraepithelial lesion
LSIL	Low-grade intraepithelial lesion
MSM	Men who have sex with men
PLHIV	Person living with HIV
SCC	Squamous cell carcinoma

SNFCP	Société Nationale Française de Colo-Proctologie
SPE	Standard proctological examination

## Introduction

In France, just over 2000 new cases of anal cancer are diagnosed annually, and the incidence of this disease is steadily increasing. The male/female sex ratio is 0.3 [1, 2]. Most anal cancers are squamous cell carcinomas (SCCs), associated with human papillomavirus (HPV) infection in 88% to 97% of cases [3], the principal virus implicated being HPV16 [4]. SCCs are preceded by precancerous lesions called squamous intraepithelial lesions. A distinction is made between low-grade squamous intraepithelial lesions (LSILs, formerly

Extended author information available on the last page of the article

p16-negative AIN1 and AIN2) and high-grade squamous intraepithelial lesions (HSILs, formerly p16-positive AIN2 and AIN3) [5].

The groups considered at greatest risk are targeting for the screening of precancerous lesions and SCC (Table 1). Three groups are considered at “very high risk” of anal cancer: (i) men who have sex with men (MSM) and are living with human immunodeficiency virus (HIV) (MSM HIV+), (ii) women with a history of HSIL or vulvar HPV cancer, and (iii) women who underwent solid organ transplantation more than 10 years ago. In these populations, the annual incidence exceeds 40/100,000 (versus 0.8 to 2.5/100,000 for the general population) [6]. Patients with a history of HSIL also warrant close monitoring and are considered to be at very high risk. Screening these “very high-risk” populations is a matter of priority and is the subject of our recommendations.

The rate of progression of HSILs to SCC varies, even within the populations at risk, and the published data are heterogeneous. In the French AIN3 cohort, the rate of progression was 1.16 per 100 patient-years [95% CI 0.84–1.47] [7]. However, progression is not always unequivocal, and the spontaneous clearance of HSILs can occur. Such clearance can occur in more than 20% of male patients at risk [8]. The factors influencing HSIL progression include the presence

of HPV16, patient age, the size of the HSILs, and immunosuppression [7, 8]. The natural course of HSILs remains imperfectly understood, but must be taken into account in the screening, treatment, and monitoring of patients at risk.

## Methods

A panel of 40 French experts (gastroenterologists, colorectal surgeons, infection specialists, virologists, epidemiologists, dermatologists, gynecologists, and pathologists) specializing in HPV infection and its manifestations reviewed the literature with a view to proposing practical management pathways for the screening of precancerous anal lesions due to HPV. Each recommendation is graded, and a management algorithm was designed for screening and monitoring.

All the authors searched the PubMed and Cochrane databases for articles published up to September 2022. An analysis of the literature was performed in accordance with the recommendations of the Haute Autorité de Santé (HAS, the French High Authority for Health), making it possible to grade the recommendations. If an absence of factual data made it impossible to establish a grade of recommendation according to HAS guidelines, then proposals based on expert opinion were drafted. If all the authors agreed on

**Table 1** Principal risk groups for anal cancer based on [6]

Populations	Annual incidence of anal cancer (per 100,000)
People living with HIV	
Men who have sex with men (MSM)*	85
<30 years old	17
Between 30 and 45 years old*	> 60
>45 years old*	≥ 100
Men who have sex with women	32
Women	22
MSM without HIV	19
Solid organ transplant patients (transplantation > 10 years ago)	
Men	24.5
Women*	50
Women with a history of HPV-related precancerous lesions/gynecological cancers	
Precancerous lesions of the cervix (CIN2 and more)	6
Cervical cancer	9
Precancerous lesions of the vagina (VAIN3)	19
Vaginal cancer	10
Precancerous lesions of the vulva (VIN3)*	42
Vulvar cancer*	45
History of autoimmune disease	
Systemic lupus erythematosus	10
Ulcerative colitis	6
Crohn's disease	3

\*Very high-risk groups targeted for screening

a consensus statement, it was then submitted to all members of the Société Nationale Française de Colo-Proctologie (SNFCP) via e-mail. Scores from 1 to 9 were assigned according to the RAND/UCLA method. The results were analyzed and statements were rewritten, if necessary, by the steering committee for this work. The resulting declarations are referred to as “expert agreements” (EAs).

## Screening for precancerous anal lesions

### Objectives of screening

The phase III randomized controlled study of the North American ANCHOR group [9] showed that the treatment of HSIL reduced the risk of progression to SCC by 57% for people living with HIV (PLHIV) after 25 months of follow-up. There were nine incident cases in the “treatment” group (i.e., 173 per 100,000 person-years, 95% CI 90–332 per 100,000 person-years) and 21 in the “surveillance” group (402 per 100,000 person-years, 95% CI 262–616 per 100,000 person-years) [9]. Moreover, the rates of SCC detection at stage I or II were higher than those reported in national data for the USA [10]. In the French AIN3 cohort, the systematic monitoring of patients with AIN3 led to the detection of 60% of SCCs at stage 1, versus only 15% in real-life conditions [7, 11]. These findings suggest that the monitoring of at-risk groups facilitates the early identification and treatment of SCC.

---

The treatment of high-grade precancerous lesions (HSILs) decreases the risk of progression to SCC. *Grade A*

Screening for precancerous anal lesions facilitates the early diagnosis of SCC, suggesting a possibility for increasing survival. *Grade C*

---

### Screening methods

#### Standard proctological examination

The standard proctological examination (SPE) includes inspection of the anal margin, a digital anorectal examination, and anoscopy. The International Anal Neoplasia Society published recommendations in 2012 for digital anorectal examinations to screen for lesions due to HPV [12]. The SPE is well tolerated, and acceptability rates are high [13–16]. Any patient presenting with proctological symptoms should undergo SPE. This examination can detect warts, macroscopically visible HSILs, and SCC at an early stage. Conversely, digital anorectal examination has a poor performance for the detection of HSILs [14]. In a prospective series of 446 men living with HIV, digital anorectal examination failed to detect any of the 156 cases of HSIL [17]. Studies on the performance of the

SPE are scarce. The strategies most frequently compared are anorectal examination, cytology, and high-resolution anoscopy (HRA). In a study reporting the results of proctological examinations on 1206 PLHIV, 26% were found to have an HPV-related anal lesion, which was limited to the anal canal in 52.7%: 9.2% had a lesion with no dysplasia, 10.2% had an LSIL, 6% an HSIL, and 0.6% cancer [14]. Another study compared different screening strategies in 212 PLHIV. The diagnostic performance of a combination of SPE, anal smear, and HR-HPV test for the detection of HSIL was significantly better than that of SPE alone, with detection rates of 12.7% versus 3.3% [18]. Finally, several studies have shown that HRA is more effective than clinical examination for HSIL screening [18–22]. Camus et al. showed that 65.7% of the HSILs detected by HRA were not visible to the naked eye [22].

---

#### 1. Conditions for performing the SPE

Symptoms, such as anal pain, swelling, and bleeding, should be checked for during the interview and, if present, a proctological examination should be performed by a gastroenterologist/proctologist. *Grade C*

Examinations of the anal margin and digital anorectal examinations can be performed by any doctor. *Grade C*

The training of patients/their partners and doctors who are not proctologists in screening makes it possible to increase the dissemination, implementation, and performance of screening. *Grade B*

Any gastroenterologist in France should be able to perform a complete proctological examination with standard anoscopy. Training in how to perform this examination and in screening for anal cancer should be an integral component of both initial and on-the-job training. *Expert agreement*

Anorectal and complete proctological examinations are rapid, cheap, and well accepted by patients. *Grade C*

Warts are mostly lesions without dysplasia or with low-grade dysplasia because they are linked to low-risk HPV. HSILs visible to the naked eye have a variable macroscopic appearance in terms of size, color, and shape. Any suspicious lesions should be biopsied to check for invasive SCC. *Grade C*

The benefit of acetic acid during a standard proctological examination has not been demonstrated. *Grade C*

Collaboration between the doctors following the populations at risk of anal cancer and gastroenterologists/proctologists must be strengthened. Each care center should define a referent proctologist if possible. *Expert agreement*

#### 2. Diagnostic performance

Detecting anal cancers at an early stage is an important goal of screening. *Grade B*

Examination of the anal margin and digital anorectal examination can detect cancers of the anus at an early stage. *Grade B*

A complete proctological examination with standard anoscopy can detect warts, macroscopically visible HSILs, and anal cancers at an early stage. *Grade C*

Screening strategies should take the availability of different screening tools into account. *Grade C*

---

### 3. Strategic limitations

The benefit of standard anoscopy-based screening for decreasing the incidence of anal cancer has not yet been demonstrated. *Grade B*  
HSILs cannot be diagnosed by digital anorectal examination. *Grade A*

Clinical examination with standard anoscopy has low sensitivity for the diagnosis of HSIL. Less than 40% of HSILs are visible to the naked eye. *Grade A*

### Anal cytology

An anal smear test involves collecting transitional cells by introducing a swab into the anal canal without prior disinfection or lubrication, at least 48 h after last sexual intercourse, in the absence of any local treatment or infection [23, 24]. Anal self-sampling (ASS) is a possible alternative, given its acceptability, feasibility, and similar diagnostic performance [25, 26]. Anal cytology should be performed only if referral for HRA is possible.

The diagnostic performance of cytology is better for the detection of histological HSILs (hHSIL) than the SPE [18]. However, this performance varies according to the population studied. In their meta-analysis, Clarke et al. found that anal cytology had a sensitivity of 81% at and above (ASC-US+) the ASC-US threshold and a specificity of 62.4% [27]. This performance is close to that of cervical smear tests [28]. For HIV+ MSM, a sensitivity of 85.2% has been reported, with a specificity of 52.8%, and a false-negative rate of 6%. The SPANC study showed that the specificity of cytology increases with age and that sensitivity increases with the size and number of HSILs [8]. In women, a sensitivity of 65.7% has been reported, with a specificity of 82.2%, and a false-negative rate of 5% [27]. Thus, for HIV+ women and MSM, anal cytology has an excellent negative predictive value. Finally, among MSM not living with HIV (HIV− MSM), cytology has been shown to have a sensitivity of only 56.6% and a specificity of 66.5%. The sensitivity of anal cytology therefore appears to be higher in HIV+ MSM. The main limitation of cytology is its lack of specificity, which can lead to HRA being performed unnecessarily. Regardless of the population, there is only a weak correlation between the grade of cytological abnormalities and the grade of histological abnormalities [29]. In cytological examinations detecting ASC-US and LSILs, the frequency of hHSIL is non-negligible [30–32]. In the meta-analysis performed by Clarke et al., the risk of hHSIL in cases of ASC-US+ abnormalities was 35%. Thus, the detection of low-grade cytological abnormalities does not rule out the presence of hHSILs. Conversely, the presence of high-grade cytological abnormalities appears to be strongly predictive of hHSIL, with a sensitivity of 21.1% and a specificity of 96.4%. Diagnostic performance, therefore, varies with the type of lesion detected (ASC-US, LSIL, or HSIL).

The combination of HPV testing and cytology appears to improve sensitivity at the expense of specificity, due to the high prevalence of high-risk HPV infection (HR-HPV) in at-risk groups [31, 33–35]. The combination of SPE, anal cytology, and tests for HPV16 increases the rate of hHSIL detection [18]. Dual-staining for p16 and Ki67 may improve the performance of anal cytology, but insufficient data are currently available to confirm this [27, 36].

#### 1. Conditions for performing anal cytology screening

Anal cytology screening should be performed in target populations. *Grade A*

The evidence for benefits of proctological screening is better for PLHIV aged  $\geq 35$  years. *Grade A*

There are insufficient data to determine the exact rate at which surveillance by anal cytology should be performed. *Grade C*

#### 2. Diagnostic performance

Anal cytology is twice as sensitive as clinical examination for the detection of HSILs. *Grade B*. However, its specificity is limited. *Grade A*

The grade of cytological abnormalities is poorly correlated with the grade of histological abnormalities. *Grade B*

The anal cytology screening strategy is indicated for high-risk populations at expert centers, but the sensitivity and specificity of the test are insufficient to justify its use for mass screening. *Grade B*

A complete strategy, defined as a combination of standard anoscopy, anal cytology, and HPV16 detection, provides higher detection rates for HSILs. *Grade B*

Most international recommendations are based on the performance of an anal smear followed by HRA if an abnormality is found. Such strategies have been the most studied, but possible association with an HPV test could lead to their evolution. *Grade C*

#### 3. Strategic limitations

Anal cytology is of marked interest in the absence of visible lesions on clinical examination. In cases of macroscopic lesions, targeted biopsies are indicated for histological analysis. *Grade B*

Anal cytology has a high sensitivity but a low specificity, leading to the risk of performing “unnecessary” HRA. *Grade A*

HRA must be performed at an expert center in the event of abnormal cytological results for patients from populations at a high risk of cancer. *Grade B*

If HRA is unavailable, the goal of screening should be the early diagnosis of anal cancer and macroscopic HSILs. *Expert agreement*

### HR-HPV screening

HR-HPV screening is based on detection of the viral genome by PCR. The intra-anal swab sample should be taken from the transitional zone [37, 38]. Several studies have demonstrated the feasibility and acceptability of ASS among HIV+ MSM [25]. Another study assessed the performance of ASS in 300 women in Zimbabwe, half of whom were living with HIV. Moderate concordance was found between the results of smears for detecting and typing HPV obtained by ASS and those for the sample taken by a clinician ( $\kappa = 0.55$ ).



The proportions of the HR-HPV types detected did not differ significantly according to the sampling method [39]. ASS may, therefore, be a suitable alternative strategy for facilitating the expansion of screening within the populations for which screening is recommended, but further studies are needed.

The test for HR-HPV is extremely sensitive for the detection of HSILs, with a sensitivity of 90% [27]. Conversely, its specificity is low, at 47% for women and only 35% for HIV+ MSM, due to the particularly high prevalence of HR-HPV infection, particularly in HIV+ MSM. One study reported a sensitivity of 75% and a specificity of 86% for the detection of HSILs in HIV+ women. HPV16 detection was also found to be very strongly predictive of HSIL lesions [40]. Another study reported similar sensitivities for HSIL detection by cytology and by the HR-HPV test, with a 67% higher specificity for the HR-HPV test than for cytology [41]. In cases in which the HR-HPV test is negative, the probability of HSIL has been estimated at 4% [27].

Restricting testing to HPV16 (rather than all HR-HPVs) decreases sensitivity, but clearly increases specificity [27, 42]. In their meta-analysis, Clarke et al. found a sensitivity of HPV16 testing for the general population of 46% and a specificity of 83%. Among HIV+ MSM, the corresponding values were 42.4% and 80.4%, respectively. However, the false-negative rate was high, at 16%. A negative HPV16 test does not, therefore, rule out the presence of HSILs [27]. However, HPV16 infection is strongly associated with SCC and is a major risk factor for the progression of HSIL to SCC [4, 7, 8, 43]. Tests for HPV16 could, therefore, make risk stratification possible, even for patients at risk. Finally, the natural course of HPV16 infection and its possible clearance justify the performance of surveillance test at 5-year intervals in the absence of signs of HPV16 infection. Indeed, Alberts et al. reported a cumulative incidence of HPV16 infection of 16% at 3 years in at-risk populations initially free of HPV16 [44]. In France, the HR-HPV test on anal swabs is not reimbursed.

#### 1. Conditions for HR-HPV testing

The entire anal canal should be swabbed, especially the anorectal transformation zone. *Grade B*

The storage of samples collected for virological purposes in a liquid cytology medium makes it possible to perform anal cytology on the same sample. *Grade A*

The diagnostic performance of self-sampling has yet to be assessed. *Grade C*

#### 2. Diagnostic performance

For patients at risk, HR-HPV testing is sensitive, but not very specific for the diagnosis of HSIL, due to a high prevalence of anal HR-HPV infection. *Grade A*

In the event of a positive HR-HPV test, a specific triage test should be considered. *Grade C*

The combination of HPV testing and anal cytology improves diagnostic performance. *Grade A*

The restriction of testing to HPV16 improves specificity but decreases sensitivity for the diagnosis of HSIL. *Grade A*

In the absence of anal HR-HPV infection, the probability of developing HSIL lesions within 5 years is low. *Grade B*

#### 3. Strategic limitations

In addition to detecting HR-HPV infection, the persistence of this infection must be evaluated. *Grade C*

The presence of HPV16 is a risk factor for the progression of HSILs to cancer. However, limiting testing to HPV16 markedly decreases the sensitivity of the test for HSIL diagnosis. *Grade B*

In France, tests for HR-HPV in anal swabs are not reimbursed

### High-resolution anoscopy

Quality criteria have been defined for HRA [45]. It is recommended that practitioners perform at least 50 HRA per year and achieve detection rate of 90% for HSIL in patients with HSIL detected on a smear in the preceding 3 months. The rate of HSIL detection increases with the number of HRAs performed [46]. The learning curve is long [47]. The examination is well tolerated, with an average VAS of 2/10 when performed for diagnostic purposes and 3/10 when the procedure includes a therapeutic maneuver, but pain remains problematic (VAS > 7/10) for 6% of men and 14% of women [48].

Published values for the sensitivity of HRA range from 59% to 100%, whereas specificity ranges from 66% to 74% [49]. Camus et al. showed that 65.7% of the high-grade lesions detected by HRA were not visible to the naked eye [22]. The presence of high-grade cytological abnormalities is predictive of a high-grade histological lesion [50]. HRA revealed the presence of AIN2+ lesions in 64% of patients with an HSIL detected on a smear [27]. However, normal or low-grade anal cytology cannot rule out the presence of hHSIL. A longitudinal study of 368 asymptomatic MSM who had undergone successive HRA examinations over a mean of 4 years showed that 11% of HSILs identified by HRA on biopsies coincided with normal smear test results [21]. In France, the APACHES study showed that 3.4% of 524 HIV MSM with HSIL diagnosed by HRA had a normal smear test and that 11.3% had a smear test result classified as ASC-US+ or LSIL [51]. These data confirm the poor concordance between the grade of cytological abnormalities and histological grade.

HRA can be difficult to perform in some patients and its use is limited in certain situations: scarred anus, stenosis, inflammation, history of radiotherapy, etc. In addition, the diagnostic performance of HRA is affected by significant interoperator variability. The APACHES study reported HSIL detection rates ranging from 5.1% to 31.3%, depending on the center, highlighting the need for rigorous training

in the practice of HRA [51]. Access to HRA is limited in France (fewer than 30 doctors perform this examination). It is not currently possible to screen all patients at risk, from the outset, by HRA. HRA is a second-line examination mostly performed after an abnormal cytology result is obtained. The development of observer-independent visualization tools based on artificial intelligence algorithms would enhance diagnostic performance and promote learning [52]. Finally, HRA makes the targeted treatment of HSILs possible [9]. However, the risk of HSIL recurrence after treatment is high (49–53% at 1 year and 66–77% at 3 years for HIV– and HIV+ MSM, respectively) and repeat examinations are therefore required [53].

### 1. Conditions for performing HRA

HRA is a second-line screening tool. It is performed after an abnormal triage test result, usually following an abnormal anal cytology result. *Grade B*

HRA is also used for the targeted treatment and monitoring of HSILs. *Grade B*

A diagnosis of HSIL is suspected in patients with a combination of staining abnormalities, abnormal vessels, and epithelial changes. Histological confirmation should systematically be sought. *Grade B*

The quality criteria for this examination are the subject of recommendations from the International Anal Neoplasia Society (IANS). *Expert agreement*

Practitioners should perform at least 50 HRAs per year. *Grade C*

### 2. Diagnostic performance

HRA is the gold standard for the detection, targeted treatment, and monitoring of HSILs. *Grade B*

HRA outperforms clinical examination with standard anoscopy for the diagnosis of HSIL. *Grade B*

It is recommended to ensure that a detection rate for high-grade lesions of 90% is obtained for patients with an HSIL-positive smear in the preceding 3 months. *Grade C*

Due to the poor correlation between anal cytology and histology results, a non-negligible proportion of patients (> 10%) with an ASC-US+ or LSIL smear have high-grade HRA lesions. *Grade B*

### 3. Strategic limitations

The natural course of high-grade lesions visible only by HRA is unknown. *Expert agreement*

The long learning curve and poor availability of this examination currently limit access to this technique. *Expert agreement*

HRA should be performed by clinicians who have received appropriate training. *Grade B*

When available, HRA should be offered to “at-risk” patients. The efficacy of strategies including HRA has been evaluated principally in MSM patients living with HIV. *Grade B*

The benefit of HRA for decreasing the incidence of anal cancer has yet to be demonstrated. *Grade B*

## Other biomarkers

The staining of anal biopsy specimens for p16<sup>INK4a</sup> (p16) and Ki-67 can help to stratify anal precancerous lesions

by differentiating HSIL from LSIL [54–58]. However, the prognostic value of these markers has yet to be established [59]. The immunocytochemical technique of p16/Ki-67 dual-staining could improve the performance of anal cytology, but the data currently available are insufficient to determine its utility [36, 60].

In the meta-analysis by Clarke et al., six studies assessed E6/E7 messenger RNA (mRNA) as markers for detecting precancerous anal lesions by two different techniques [27]. The sensitivity was only 74.2%, with a high false-negative rate of 16% for HSIL diagnosis. The specificity was 64.3% [27]. The small number of studies and their heterogeneity highlight the need to continue the evaluation of these markers.

Finally, methylation (host genome and viral DNA) markers are promising in terms for triage purposes, to identify high-grade anal lesions with various degrees of risk of progression to cancer [61–63]. The study of two methylation markers (ZNF582 and ASCL1) in a cross-sectional analysis of smears from the French AIN3 cohort revealed an association between the hypermethylation of these markers on a smear at a given time and a high risk of progression to SCC [7]. The evaluation of these markers should be continued.

The objective of biomarker use is to improve the specificity of anal cytology and the detection of HR-HPV. *Grade B*

### P16/Ki-67 dual-staining

#### 1. Conditions for performing p16/Ki-67 dual-staining

Dual-staining for p16/Ki-67 can be performed on cytological or histological samples

#### 2. Diagnostic performance

The p16 marker can be used to differentiate LSIL from HSIL histologically. *Grade A*

The diagnostic performance of dual-staining for p16 and Ki-67 in immunocytochemistry is not superior to that of cytology alone for the diagnosis of HSIL. *Grade C*

p16/Ki-67 dual-staining is less sensitive but more specific than testing for HR-HPV for the diagnosis of HSIL. *Grade C*

#### 3. Strategic limitations

The diagnostic value of dual p16/Ki-67 dual-staining alone or in combination with anal cytology has not been demonstrated. *Grade C*

Staining for p16 may be of prognostic value but this requires confirmation. *Grade C*

### Methylation

#### 1. Conditions for methylation marker use

Methylation markers can be analyzed on cytological or histological samples

#### 2. Diagnostic performance

It is not possible to assess the diagnostic performance of methylation markers on the basis of the data currently published. *Grade C*

Methylation markers may be of prognostic value for predicting the progression of HSIL to cancer. *Expert agreement*

3. Strategic limitations  
 The diagnostic and prognostic values of methylation markers have yet to be demonstrated. Studies are underway. *Grade C*

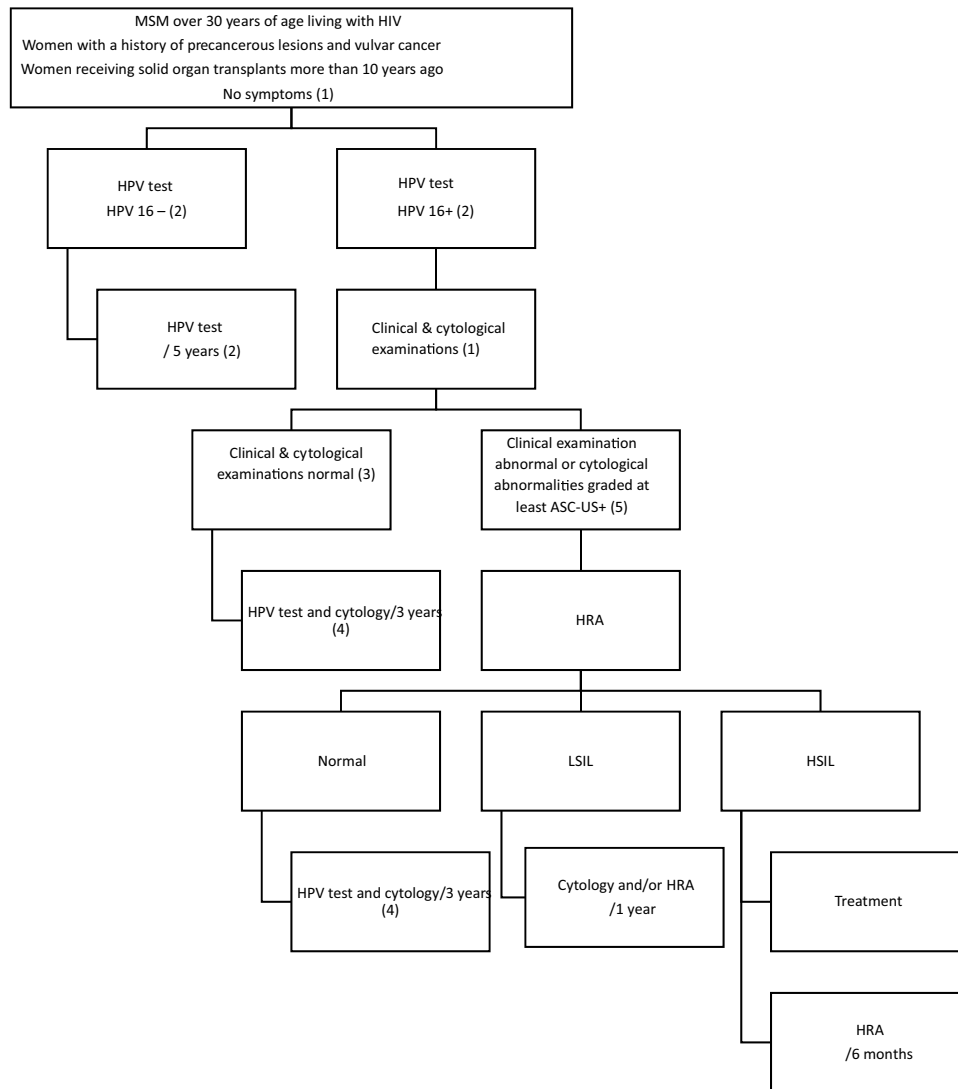
E6/E7 mRNA

1. Conditions for E6/E7 mRNA use  
 The presence of mRNA encoding the E6/E7 oncoproteins is a sign of active HR-HPV infection  
 These transcripts are sought in cytological samples

2. Diagnostic performance  
 The diagnostic performance of testing for the presence of E6/E7 mRNA is not superior to cytology alone for the diagnosis of HSIL. *Grade C*

3. Strategic limitations  
 The diagnostic value of testing for the presence of E6/E7 mRNA alone or in combination with anal cytology has not been demonstrated. *Grade C*

**Algorithm**



(1) SPE is essential if the patient presents proctological symptoms.



- (2) The search for viral signs of HPV16 infection is at the heart of triage tests because this virus is associated with SCC of the anal canal with a very high prevalence. This strategy limits the need for specialist consultation. The natural course of HPV16 infection and its potential clearance make it possible to perform surveillance tests at 5-year intervals in the absence of signs of HPV16 infection. The cumulative incidence of HPV16 infection is 16% at 3 years for populations at risk without prior HPV16 infection [44].
- (3) On the basis of current knowledge, a normal cytological examination result renders the presence of HSIL very unlikely (4%).
- (4) In the presence of HPV16 infection and a normal clinical examination, clearance of the virus is slow and observed in only just over one-third of patients after 3 years of follow-up [44, 64]. It does not, therefore, appear useful to repeat testing at too short an interval in this population, especially if the results of the clinical examination are normal. A normal cytological examination result renders the occurrence of HSIL within 3 years unlikely.
- (5) The presence of cytological abnormalities is associated with HSIL in one-third of all cases, and two-thirds of cases of high-grade cytological lesions. Pending more discriminating non-invasive tests (methylation test, P16/Ki-67 staining), HRA should be performed under optimal conditions, with biopsies. If HRA is not possible, a SPE must be repeated at least once annually.

#### 1. Usable strategies and diagnostic performance

The most widely used triage tests are virological tests to detect HR-HPV and liquid-phase anal cytology. The first of these methods is the most sensitive (4% false negatives) and the second is the most specific (64% true positives in the presence of HSIL). The use of these two tests is recommended in patients with risk factors for dysplasia and cancer. *Grade A*

In theory, initial use of an HPV test (with HPV16 genotyping) could be preferred, with positive results leading to the performance of anal cytology. *Grade B*

Other specific tests have not been adequately studied and cannot yet be recommended in routine practice. *Grade B*

#### 2. Strategic limitations

Given the intercenter and interobserver variability of the diagnosis of anal dysplasia, it is recommended that the practitioners and pathologists responsible for making positive diagnoses of dysplasia undergo prior training and compare their diagnostic performances. *Grade B*

The testing of screening protocols in real-life conditions is recommended, to analyze the compliance of at-risk individuals and the conditions for reimbursement of the tests. *Grade C*

Within the framework of screening for the early diagnosis and monitoring of lesions of dysplasia, the management and reimbursement of virological tests and cytological analyses by public authorities is important, as is the specific consideration of HRA

## Conclusion

The incidence of SCC of the anus is steadily increasing. Screening for precancerous anal lesions is a public health issue. The objective should no longer be solely the early diagnosis of cancer but rather the prevention of cancer through the diagnosis and treatment of precancerous anal lesions. Screening is targeted to groups at risk. The performance of a first-line test for HPV16 makes it possible to select the patients for whom the risk of precancerous lesions progressing to SCC is highest, even with the population of high-risk patients. HRA occupies a central position in the detection and management of patients. Its development must be a matter of priority. Further evaluations of triage tests and biomarkers, such as p16/Ki67 and E6/E7 mRNA, and the development of prognostic markers, such as methylation markers, are required. Along with the screening of asymptomatic patients, it is essential for all patients presenting proctological symptoms to undergo a complete proctological examination. In any case, screening strategies warrant further evaluation.

**Data availability** All data generated or analysed during this study are included in this published article [and its supplementary information files].

## Declarations

**Conflict of interest** Lucas Spindler, Vincent de Parades, Nadia Fathallah, Liza Kassouri, Simon Kurt and Deborah Roland have been approached by the THD laboratory for the financial support concerning the organization of symposia “Journée colo-proctologique de printemps de Saint-Joseph”.

Isabelle Etienney, Laurent Abramowitz and Amelie Menard have been approached by the MSD laboratory for oral presentations and advice. Charlotte Charpentier and Valentine Ferre have been approached by the Seegene and Copan laboratories for technical support concerning the laboratory tests used for previously studies about HPV.

Helene Pere have been approached by the MSD, Seegene, Janssen and ViiV laboratories for oral presentations, advice and financial support for attending symposia.

The other authors have no conflicts of interest to declare.

**Ethical approval** No ethical approval is required for clinical practice guidelines of French Society of Coloproctology.

**Informed consent** For this type of study, formal consent is not required.

**Open Access** This article is licensed under a Creative Commons Attribution 4.0 International License, which permits use, sharing, adaptation, distribution and reproduction in any medium or format, as long as you give appropriate credit to the original author(s) and the source, provide a link to the Creative Commons licence, and indicate if changes were made. The images or other third party material in this article are included in the article’s Creative Commons licence, unless indicated otherwise in a credit line to the material. If material is not included in the article’s Creative Commons licence and your intended use is not permitted by statutory regulation or exceeds the permitted use, you will

need to obtain permission directly from the copyright holder. To view a copy of this licence, visit <http://creativecommons.org/licenses/by/4.0/>.


## References

- Institut National du Cancer (2019) Les cancers en France, l'essentiel des faits et chiffres. [https://e-cancer.fr/content/download/255246/3573612/file/Cancers\\_en\\_France-Essentiel\\_Faits\\_et\\_chiffres-2018.pdf](https://e-cancer.fr/content/download/255246/3573612/file/Cancers_en_France-Essentiel_Faits_et_chiffres-2018.pdf). Accessed 18 Dec 2023
- Moureau-Zabotto L, Vendrely V, Abramowitz L et al (2022) Cancer du canal anal. Thésaurus National de Cancérologie Digestive. <http://www.tncd.org>. Accessed 18 Dec 2023
- Abramowitz L, Lacau Saint Guily J, Moyal-Barracco M et al (2018) Epidemiological and economic burden of potentially HPV-related cancers in France. *PLoS ONE* 13:e0202564
- Lin C, Franceschi S, Clifford GM (2018) Human papillomavirus types from infection to cancer in the anus, according to sex and HIV status: a systematic review and meta-analysis. *Lancet Infect Dis* 18:198–206
- Darragh TM, Colgan TJ, Thomas Cox J et al (2013) The Lower Anogenital Squamous Terminology Standardization project for HPV-associated lesions: background and consensus recommendations from the College of American Pathologists and the American Society for Colposcopy and Cervical Pathology. *Int J Gynecol Pathol* 32:76–115
- Clifford GM, Georges D, Shiels MS et al (2021) A meta-analysis of anal cancer incidence by risk group: toward a unified anal cancer risk scale. *Int J Cancer* 148:38–47
- Valette E, Draullette M, Abramowitz L et al (2021) Incidence et facteurs de risque de carcinome épidermoïde de l'anus en cas de dysplasie anale sévère AIN 3: une étude de cohorte prospective et multicentrique. *JFHOD 2021 CO.038*
- Poynten IM, Jin F, Roberts JM et al (2021) The natural history of anal high-grade squamous intraepithelial lesions in gay and bisexual men. *Clin Infect Dis* 72:853–861
- Palefsky JM, Lee JY, Jay N et al (2022) Treatment of anal high-grade squamous intraepithelial lesions to prevent anal cancer. *N Engl J Med* 386:2273–2282
- Deshmukh AA, Suk R, Shiels MS et al (2020) Recent trends in squamous cell carcinoma of the anus incidence and mortality in the United States, 2001–2015. *J Natl Cancer Inst* 112:829–838
- Abramowitz L, Mathieu N, Roudot-Thoraval F et al (2009) Epidermoid anal cancer prognosis comparison among HIV infected and non-infected patients: a multicentric cohort study in 151 patients. *Alim Pharm Ther* 30:414–421
- Hillman RJ, Berry-Lawhorn JM, Ong JJ et al (2019) International Anal Neoplasia Society guidelines for the practice of digital anal rectal examination. *J Low Genit Tract Dis* 23:138–146
- Ong JJ, Fairley CK, Carrol S et al (2016) Cost-effectiveness of screening for anal cancer using regular digital ano-rectal examinations in men who have sex with men living with HIV. *J Int AIDS Soc* 19:20514
- Abramowitz L, Benabderrahmane D, Walker F et al (2016) Determinants of macroscopic anal cancer and precancerous lesions in 1206 HIV-infected screened patients. *Colorectal Dis* 18:997–1004
- Landstra JMB, Ciarrochi J, Deane FP, Botes LP, Hillman RJ (2013) The psychological impact of anal cancer screening on hiv-infected men: psychological impact of anal cancer screening. *Psychooncology* 22:614–620
- Tinmouth J, Raboud J, Ali M et al (2011) The psychological impact of being screened for anal cancer in HIV-infected men who have sex with men. *Dis Colon Rectum* 54:352–359
- Kreuter A, Potthoff A, Brockmeyer NH et al (2010) Anal carcinoma in human immunodeficiency virus-positive men: results of a prospective study from Germany. *Br J Dermatol* 162:1269–1277
- Pernot S, Boucheron P, Péré H et al (2018) Comparison of anal cancer screening strategies including standard anoscopy, anal cytology, and HPV genotyping in HIV-positive men who have sex with men. *Br J Cancer* 119:381–386
- Bull-Henry K, Morris B, Buchwald UK (2020) The importance of anal cancer screening and high-resolution anoscopy to gastroenterology practice. *Curr Opin Gastroenterol* 36:393–401
- Berry JM, Jay N, Cranston RD et al (2014) Progression of anal high-grade squamous intraepithelial lesions to invasive anal cancer among HIV-infected men who have sex with men. *Int J Cancer* 134:1147–1155
- Dalla Pria A, Alfa-Wali M, Fox P et al (2014) High-resolution anoscopy screening of HIV-positive MSM: longitudinal results from a pilot study. *AIDS* 28:861–867
- Camus M, Lesage AC, Fléjou JF, Hoyeau N, Atienza P, Etienney I (2015) Which lesions should be biopsied during high-resolution anoscopy? Prospective descriptive study of simple morphological criteria. *J Low Genit Tract Dis* 19:156–160
- Michael Berry J, Palefsky JM, Welton ML (2004) Anal cancer and its precursors in HIV-positive patients: perspectives and management. *Surg Oncol Clin N Am* 13:355–373
- Bean SM, Chhieng DC (2010) Anal-rectal cytology: the other pap test. *Lab Med* 41:168–171
- Heid-Picard B, Cochand-Priollet B, Rozenberg F et al (2021) Ambulatory anal self-sampling in MSM living with HIV, an acceptable and reliable screening method. *PLoS ONE* 16:e0246338
- Lampinen TM, Miller ML, Chan K et al (2006) Randomized clinical evaluation of self-screening for anal cancer precursors in men who have sex with men. *CytoJournal* 3:4
- Clarke MA, Deshmukh AA, Suk R et al (2022) A systematic review and meta-analysis of cytology and HPV-related biomarkers for anal cancer screening among different risk groups. *Int J Cancer* 151:1889–1901
- Fox PA (2005) The value of anal cytology and human papillomavirus typing in the detection of anal intraepithelial neoplasia: a review of cases from an anoscopy clinic. *Sex Transm Infect* 81:142–146
- Chiao EY, Giordano TP, Palefsky JM, Tyring S, Serag HE (2006) HIV/AIDS: screening HIV-infected individuals for anal cancer precursor lesions: a systematic review. *Clin Infect Dis* 43:223–233
- Gonçalves JCN, Macedo ACL, Madeira K et al (2019) Accuracy of anal cytology for diagnostic of precursor lesions of anal cancer: systematic review and meta-analysis. *Dis Colon Rectum* 62:112–120
- Clarke MA, Wentzensen N (2018) Strategies for screening and early detection of anal cancers: a narrative and systematic review and meta-analysis of cytology, HPV testing, and other biomarkers. *Cancer Cytopathol* 126:447–460
- Binda GA, Gagliardi G, Dal Conte I et al (2019) Practice parameters for the diagnosis and treatment of anal intraepithelial neoplasia (AIN) on behalf of the Italian Society of Colorectal Surgery (SICCR). *Tech Coloproctology* 23:513–528
- Berry JM, Palefsky JM, Jay N, Cheng SC, Darragh TM, Ching-Hong PV (2009) Performance characteristics of anal cytology and human papillomavirus testing in patients with high-resolution anoscopy-guided biopsy of high-grade anal intraepithelial neoplasia. *Dis Colon Rectum* 52:239–247

34. Etienney I, Vuong S, Si-Mohamed A et al (2012) Value of cytologic Papanicolaou smears and polymerase chain reaction screening for human papillomavirus DNA in detecting anal intraepithelial neoplasia: comparison with histology of a surgical sample. *Cancer* 118:6031–6038
35. Iribarren Díaz M, Ocampo Hermida A, González-Carreró Fojón J et al (2017) Preliminary results of a screening program for anal cancer and its precursors for HIV-infected men who have sex with men in Vigo-Spain. *Rev Esp Enfermedades Dig* 109:242–249
36. Arora R, Pandhi D, Mishra K, Bhattacharya SN, Yhome VA (2014) Anal cytology and p16 immunostaining for screening anal intraepithelial neoplasia in HIV-positive and HIV-negative men who have sex with men: a cross-sectional study. *Int J STD AIDS* 25:726–733
37. Bean SM, Chhieng DC (2010) Anal-rectal cytology: a review. *Diagn Cytopathol* 38:538–546
38. Vuitton L, Jacquin E, Parmentier AL et al (2018) High prevalence of anal canal high-risk human papillomavirus infection in patients with Crohn's disease. *Clin Gastroenterol Hepatol* 16:1768–1776
39. Dube Mandishora RS, Rounge TB, Fitzpatrick M et al (2021) Self-collected and clinician-collected anal swabs show modest agreement for HPV genotyping. *PLoS ONE* 16:e0250426
40. Ellsworth GB, Stier EA, Chiao EY et al (2021) Xpert HPV as a screening tool for anal histologic high-grade squamous intraepithelial lesions in women living with HIV. *J Acquir Immune Defic Syndr* 87:978–984
41. Chiao EY, Lensing SY, Wiley DJ et al (2020) Screening strategies for the detection of anal high-grade squamous intraepithelial lesions in women living with HIV. *AIDS* 34:2249–2258
42. Clarke MA, Cheung LC, Lorey T et al (2019) 5-year prospective evaluation of cytology, human papillomavirus testing, and biomarkers for detection of anal precancer in human immunodeficiency virus-positive men who have sex with men. *Clin Infect Dis* 69:631–638
43. Burgos J, Curran A, Tallada N et al (2015) Risk of progression to high-grade anal intraepithelial neoplasia in HIV-infected MSM. *AIDS* 29:695–702
44. Alberts CJ, Heard I, Canestri A et al (2020) ANRS EP57 APACHES Study group. Incidence and clearance of anal human papillomavirus (HPV)-16 and HPV-18 infection, and their determinants, among human immunodeficiency virus-infected men who have sex with men in France. *J Infect Dis* 221:1488–1493
45. Hillman RJ, Cuming T, Darragh T et al (2016) IANS International guidelines for practice standards in the detection of anal cancer precursors. *J Low Genit Tract Dis* 20:283–291
46. Siegenbeek van Heukelom ML, Marra E, Cairo I et al (2018) Detection rate of high-grade squamous intraepithelial lesions as a quality assurance metric for high-resolution anoscopy in HIV-positive men. *Dis Colon Rectum* 61:780–786
47. Neukam K, Milanés Guisado Y, Fontillón M et al (2019) High-resolution anoscopy in HIV-infected men: assessment of the learning curve and factors that improve the performance. *Papillomavirus Res* 7:62–66
48. De-Masi A, Davis E, Cuming T et al (2018) The acceptability of high resolution anoscopy examination in patients attending a tertiary referral centre. *BMC Cancer* 18:554
49. Gimenez F, da Costa-e-Silva IT, Daumas A, de Araújo J, Medeiros SG, Ferreira L (2011) The value of high-resolution anoscopy in the diagnosis of anal cancer precursor lesions in HIV-positive patients. *Arq Gastroenterol* 48:136–145
50. Nathan M, Singh N, Garrett N, Hickey N, Prevost T, Sheaff M (2010) Performance of anal cytology in a clinical setting when measured against histology and high-resolution anoscopy findings. *AIDS* 24:373–379
51. Clifford GM, Siproudhis L, Piroth L et al (2018) Determinants of high-grade anal intraepithelial lesions in HIV-positive MSM. *AIDS* 32:2363–2371
52. Saraiva MM, Spindler L, Fathallah N et al (2022) Artificial intelligence and high-resolution anoscopy: automatic identification of anal squamous cell carcinoma precursors using a convolutional neural network. *Tech Coloproctol* 26:893–900
53. Goldstone SE, Johnstone AA, Moshier EL (2014) Long-term outcome of ablation of anal high-grade squamous intraepithelial lesions: recurrence and incidence of cancer. *Dis Colon Rectum* 57:316–323
54. Bean SM, Eltoum I, Horton DK, Whitlow L, Chhieng DC (2007) Immunohistochemical expression of p16 and Ki-67 correlates with degree of anal intraepithelial neoplasia. *Am J Surg Pathol* 31:555–561
55. Chen CC, Hsueh KC, Shen CH, Bai CH, Wu CC, Wang YH (2020) The diagnostic value of p16/ki67 dual immunostaining for anal intraepithelial neoplasia: a meta-analysis. *Am J Mens Health* 14:1557988320977630
56. Walts AE, Lechago J, Bose S (2006) P16 and Ki67 immunostaining is a useful adjunct in the assessment of biopsies for HPV-associated anal intraepithelial neoplasia. *Am J Surg Pathol* 30:795–801
57. Liu Y, McCluggage WG, Darragh TM et al (2021) Classifying anal intraepithelial neoplasia 2 based on LAST recommendations. *Am J Clin Pathol* 155:845–852
58. Krishnamurti U, Mohammad M, Monsrud A et al (2020) Diagnosing anal squamous intraepithelial lesions with and without p16: an interobserver variability study. *J Low Genit Tract Dis* 24:69–74
59. Albuquerque A, Rios E, Medeiros R (2019) Beyond p16 immunostaining: an overview of biomarkers in anal squamous intraepithelial lesions. *Histol Histopathol* 34:201–212
60. Pichon M, Joly M, Lebreton F, Benchaïb M, Mekki Y, Devouassoux-Shisheboran M (2019) Evaluation of p16/ki-67 dual staining compared with HPV genotyping in anal cytology with diagnosis of ASC-US for detection of high-grade anal intraepithelial lesions. *J Cytol* 36:152–156
61. van der Zee RP, Richel O, van Noesel CJM et al (2019) Host cell deoxyribonucleic acid methylation markers for the detection of high-grade anal intraepithelial neoplasia and anal cancer. *Clin Infect Dis Off* 68:1110–1117
62. van der Zee RP, van Noesel CJM, Martin I et al (2021) DNA methylation markers have universal prognostic value for anal cancer risk in HIV-negative and HIV-positive individuals. *Mol Oncol* 15:3024–3036
63. van der Zee RP, Richel O, van Noesel CJM et al (2021) Cancer risk stratification of anal intraepithelial neoplasia in human immunodeficiency virus-positive men by validated methylation markers associated with progression to cancer. *Clin Infect Dis* 72:2154–2163
64. Wei F, Xia N, Ocampo R et al (2023) Age-specific prevalence of anal and cervical HPV infection and high-grade lesions in 11 177 women by HIV status: a collaborative pooled analysis of 26 studies. *J Infect Dis* 227:488–497

**Publisher's Note** Springer Nature remains neutral with regard to jurisdictional claims in published maps and institutional affiliations.

## Authors and Affiliations

L. Spindler<sup>1</sup>  · I. Etienney<sup>2</sup> · L. Abramowitz<sup>3</sup> · V. de Parades<sup>1</sup> · F. Pigot<sup>4</sup> · L. Siproudhis<sup>5</sup> · J. Adam<sup>6</sup> · V. Balzano<sup>7</sup> · D. Bouchard<sup>4</sup> · N. Bouta<sup>8</sup> · M. Bucau<sup>9</sup> · A. Carlo<sup>5</sup> · J. Chanal<sup>10</sup> · C. Charpentier<sup>11</sup> · G. Clifford<sup>12</sup> · M. Draullette<sup>13</sup> · N. Fathallah<sup>1</sup> · V. Ferré<sup>11</sup> · J.-F. Fléjou<sup>14</sup> · S. Fouéré<sup>15,16</sup> · T. Higuero<sup>17</sup> · L. Kassouri<sup>1</sup> · S. Kurt<sup>1</sup> · A. Laurain<sup>3</sup> · E. Leclerc<sup>18</sup> · Q. Lepiller<sup>19</sup> · A.-C. Lesage<sup>2</sup> · D. Mège<sup>20</sup> · A. Ménard<sup>21</sup> · P. Merle<sup>8</sup> · P. Mortreux<sup>22</sup> · C. Noël<sup>23</sup> · H. Péré<sup>24,25</sup> · J.-L. Prétet<sup>26,27</sup> · D. Roland<sup>1</sup> · G. Staumont<sup>8</sup> · L. Tracanelli<sup>4</sup> · L. Vuitton<sup>28</sup> · S. Wylomanski<sup>29</sup> · O. Zaegel-Faucher<sup>30</sup> · Société Nationale Française de Colo-Proctologie

✉ L. Spindler  
lspindler@ghpsj.fr

<sup>1</sup> Service de Proctologie, Groupe Hospitalier Paris Saint-Joseph, Paris, France

<sup>2</sup> Service de Proctologie, Hôpital Diaconesses-Croix Saint Simon, Paris, France

<sup>3</sup> Service de Proctologie, APHP Hôpital Bichat-Claude Bernard and Ramsay GDS Clinique Blomet, Paris, France

<sup>4</sup> Service de Proctologie, Hôpital Bagatelle, Talence, France

<sup>5</sup> Service d'Hépatogastroentérologie, CHU Pontchaillou, Rennes, France

<sup>6</sup> Service d'Anatomopathologie, Groupe Hospitalier Paris Saint-Joseph, Paris, France

<sup>7</sup> Service de Gastroentérologie et Oncologie Digestive, CHU Tours, Tours, France

<sup>8</sup> Service d'Hépatogastroentérologie et de Proctologie, Clinique La Croix du Sud, Quint-Fonsegrives, France

<sup>9</sup> Service d'Anatomopathologie, AP-HP Hôpital Bichat-Claude Bernard, Paris, France

<sup>10</sup> Service de Dermatologie, AP-HP, Hôpital Tarnier, Paris, France

<sup>11</sup> Département de Virologie, AP-HP, Hôpital Bichat-Claude Bernard, INSERM, IAME, Université de Paris, Paris, France

<sup>12</sup> Early Detection, Prevention, and Infections Branch, International Agency for Research On Cancer, Lyon, France

<sup>13</sup> Service d'Hépatogastroentérologie et Assistance Nutritive, AP-HP, Hôpital Beaujon, Clichy, France

<sup>14</sup> Service d'Anatomopathologie, Cerbapath, Paris, France

<sup>15</sup> Service de Dermatologie, AP-HP, Hôpital Saint-Louis, Université de Paris, Paris, France

<sup>16</sup> Centre des Maladies Sexuellement Transmises, AP-HP, Hôpital Saint-Louis, Paris, France

<sup>17</sup> Gastro-entérologue, proctologue medico-chirurgical, Beausoleil, France

<sup>18</sup> Service d'Hépatogastroentérologie, CHU Clermont-Ferrand, Inserm, 3iHP, Université Clermont Auvergne, Clermont-Ferrand, France

<sup>19</sup> Laboratoire de Virologie, CHU de Besançon, Besançon, France

<sup>20</sup> Service de Chirurgie Digestive, Université d'Aix Marseille, AP-HM, Hôpital de la Timone, Marseille, France

<sup>21</sup> Institut Hospitalo-Universitaire Méditerranée Infection, AP-HM, Hôpital Nord, Université d'Aix Marseille, Marseille, France

<sup>22</sup> Service de Gastroentérologie, Centre Hospitalier de Bethune Beuvry, Beuvry, France

<sup>23</sup> Service d'Hépatogastroentérologie, CHU de Brest, Brest, France

<sup>24</sup> Laboratoire de Virologie, Service de Microbiologie, AP-HP, Hôpital Européen Georges Pompidou, Paris, France

<sup>25</sup> Functional Genomics of Solid Tumors (FunGeST), Centre de Recherche des Cordeliers, INSERM, Université de Paris, Sorbonne Université, Paris, France

<sup>26</sup> EA3181, Université de Franche-Comté, LabEx LipSTIC ANR-11-LABX-0021, Besançon, France

<sup>27</sup> Centre National de Référence Papillomavirus, CHU de Besançon, Besançon, France

<sup>28</sup> Service de Gastroentérologie, CHU de Besançon, Université de Bourgogne Franche-Comté, Besançon, France

<sup>29</sup> Service de Gynécologie, Groupe Hospitalier Paris Saint-Joseph, Paris, France

<sup>30</sup> Service d'Immuno-Hématologie Clinique, AP-HM, CHU Sainte-Marguerite, Marseille, France