



**HAL**  
open science

## Novel variant in LRP6 associated with unusual and severe clinical presentation: Case report

Anaïk Previdi, Christèle Dubourg, Valérie Cormier Daire, Mélanie Fradin,  
Corinne Collet

### ► To cite this version:

Anaïk Previdi, Christèle Dubourg, Valérie Cormier Daire, Mélanie Fradin, Corinne Collet. Novel variant in LRP6 associated with unusual and severe clinical presentation: Case report. *Clinical Genetics*, 2024, 105 (6), pp.666-670. 10.1111/cge.14501 . hal-04600860

**HAL Id: hal-04600860**

**<https://u-paris.hal.science/hal-04600860>**

Submitted on 4 Jun 2024

**HAL** is a multi-disciplinary open access archive for the deposit and dissemination of scientific research documents, whether they are published or not. The documents may come from teaching and research institutions in France or abroad, or from public or private research centers.

L'archive ouverte pluridisciplinaire **HAL**, est destinée au dépôt et à la diffusion de documents scientifiques de niveau recherche, publiés ou non, émanant des établissements d'enseignement et de recherche français ou étrangers, des laboratoires publics ou privés.



Distributed under a Creative Commons Attribution 4.0 International License

## SHORT REPORT

# Novel variant in *LRP6* associated with unusual and severe clinical presentation: Case report

Anaïk Previdi<sup>1</sup> | Christèle Dubourg<sup>2,3</sup> | Valérie Cormier Daire<sup>4</sup> | Mélanie Fradin<sup>5</sup> | Corinne Collet<sup>1,3,4</sup>

<sup>1</sup>UFR de Pharmacie, Université Paris Cité, Paris, France

<sup>2</sup>Service de Génétique Moléculaire, CHU Rennes, Hôpital Sud, CLAD Ouest, Rennes, France

<sup>3</sup>Laboratoire de Biologie Médicale Multisites Seqoia-FMG2025, Paris, France

<sup>4</sup>Département de Génétique, INSERM UMR1163, Institut Imagine, CHU Necker-Enfants Malades, Paris, France

<sup>5</sup>Service de Génétique Clinique, CHU Rennes, Hôpital Sud, CLAD Ouest, Rennes, France

## Correspondence

Corinne Collet, Département de Génétique, INSERM UMR1163, Institut Imagine, CHU Necker-Enfants Malades, 24, Bd du Montparnasse, Paris, France.  
Email: [corinne.collet@aphp.fr](mailto:corinne.collet@aphp.fr)

## Abstract

Low-density lipoprotein receptor-related protein 6 (*LRP6*) is a co-receptor of the Wnt signaling pathway, which plays an essential role in various biological activities during embryonic and postnatal development. *LRP6* is exceptionally associated with rare diseases and always with autosomal dominant inheritance. Here we report a familial phenotype of high bone mass associated with skeletal anomalies and oligodontia but also persistent left superior vena cava, inguinal hernia, hepatic cysts, abnormal posterior fossa and genital malformations. Molecular analysis revealed a novel heterozygous variant, NM\_002336.2: c.724T>C, p.(Trp242Arg), in affected individuals. This variant is located in the first  $\beta$ -propellant motif of *LRP6*, to which sclerostin (*SOST*) and dickkopf1 (*DKK1*), two *LRP6* co-receptor inhibitors and various Wnt ligands bind. According to the literature and integrating data from structural analysis, this variant distorts the binding of *SOST* and *DKK1*, thus leading to overactivation of Wnt signaling pathways involved in osteoblast differentiation. This novel heterozygous variant in *LRP6* underlies the role of *LRP6* in skeletal and dental disorders as well as, probably, cardiac, cerebral and genital developments.

## KEYWORDS

*LRP6*, multiple abnormalities, Wnt pathway

## 1 | INTRODUCTION

Recently, pathogenic variants in the *LRP6* co-receptor, member of the canonical Wnt pathway, were described in the high bone mass phenotype.<sup>1–3</sup> *LRP6* gene encodes a member of the low-density lipoprotein membrane receptor (LDLR) superfamily, which include *LRP5* and *LRP4*, but only *LRP6* shares very high homology with *LRP5*.<sup>4</sup> They are both co-receptors for frizzled receptors to which similar and different Wnt ligands bind.<sup>4</sup> The *LRP5* or *LRP6*/Wnt ligand/frizzled receptor complex is required to activate the Wnt/ $\beta$ -catenin (canonical)

signaling pathway, which is essential for various biological activities such as embryonic development and cell proliferation, including early osteoblastic differentiation.<sup>5</sup> Both are involved in osteoblast differentiation during postnatal bone acquisition, but they also present divergent functions especially during embryogenesis.<sup>5,6</sup> Mice with *Lrp6* knockout die at birth and have various severe developmental abnormalities, including truncation of the axial skeleton, mid/hindbrain defects, limb defects, microphthalmia, and urogenital malformation.<sup>7</sup> Moreover, unlike *LRP5*, *LRP6* has never been associated with a recessive disease in humans.<sup>8</sup> At the heterozygous level, *LRP6* variants have been reported in tooth agenesis type 7 (OMIM 616724). Also, *LRP6* is associated with coronary artery disease in patients with metabolic

Mélanie Fradin and Corinne Collet contributed equally to this study.

This is an open access article under the terms of the [Creative Commons Attribution](https://creativecommons.org/licenses/by/4.0/) License, which permits use, distribution and reproduction in any medium, provided the original work is properly cited.

© 2024 The Authors. *Clinical Genetics* published by John Wiley & Sons Ltd.

disease characterized by hypertension, hypercholesterolemia, hypertriglyceridemia, diabetes mellitus and gout (OMIM 610947).<sup>9</sup> Both syndromes are autosomal dominantly inherited. Involvement of *LRP6* in early-onset osteoporosis and spina bifida has also been strongly suggested, but few publications have been reported.<sup>8</sup> Finally, *LRP6* heterozygous variants have been described in high bone mass, associated or not with oligodontia.<sup>1–3,10</sup> Phenotypes associated with variants localized in the first  $\beta$ -propeller motifs seem to result from gain-of-function variants, which prevent binding of dickkopf1 (DDK1) and/or *SOST*, inhibitors of the canonical Wnt pathway, thereby activating this signaling.<sup>11</sup>

Here, we described a novel heterozygous variant in *LRP6* that segregates in a family with high bone mass associated with skeletal, dental, cerebral, genital, and cardiac abnormalities.

## 2 | MATERIALS AND METHODS

See [Supplementary data](#).

## 3 | RESULTS

### 3.1 | Case report

The proband, a 36-year-old woman, has been followed since childhood for skeletal and dental abnormalities. She was born from two healthy unrelated parents. She had surgery at age 4 to correct severe scoliosis with L4 hemivertebra in the context of an oblique sacrum and absence of vertebral discs in L5 and S1. Some of the spina bifida occulta was associated with L5 and S1 malformation (Figure 1A) ([Supplementary data](#)). At the time of the surgery, osteopetrosis was suggested. Subsequent X-rays confirmed osteosclerosis in metaphysis of long bones and thickening of the skull base (Figure 1B). The first pain appeared at age 8 years, concomitant with an episode of transient synovitis. The girl experienced lower limb pain, tiredness, and headaches. Oligodontia was diagnosed at age 12, and at adult age, only 4 permanent teeth were detected. However, she never had a bone fracture. In addition, during adulthood, a bicornate uterus and an inguinal hernia were discovered. At the central nervous system level, the woman had mega cisterna magna and ventricular dilatation, for which drainage was suggested (Figure 1C,D). Moreover, persistent left superior vena cava was detected after cardiac echography. The woman does not have digestive tract or ophthalmological issues. All data are presented in Table 1. The woman's father is deceased, but he had no signs of dental or bone problems. Her mother is healthy.

The woman's first son was born at 38 weeks' gestation with normal parameters. At birth, he had multiple angiomas on his back and chest. The angiomas decreased from age 4 months. At age 1 month, the boy underwent surgery for pyloric stenosis and an inguinal hernia. At 4 months old, X-rays showed osteosclerosis at skull base, long bones and vertebrae associated with L5-S1 hemivertebra and scoliosis (Figure 2A). Osteosclerosis was associated with a dental articulation

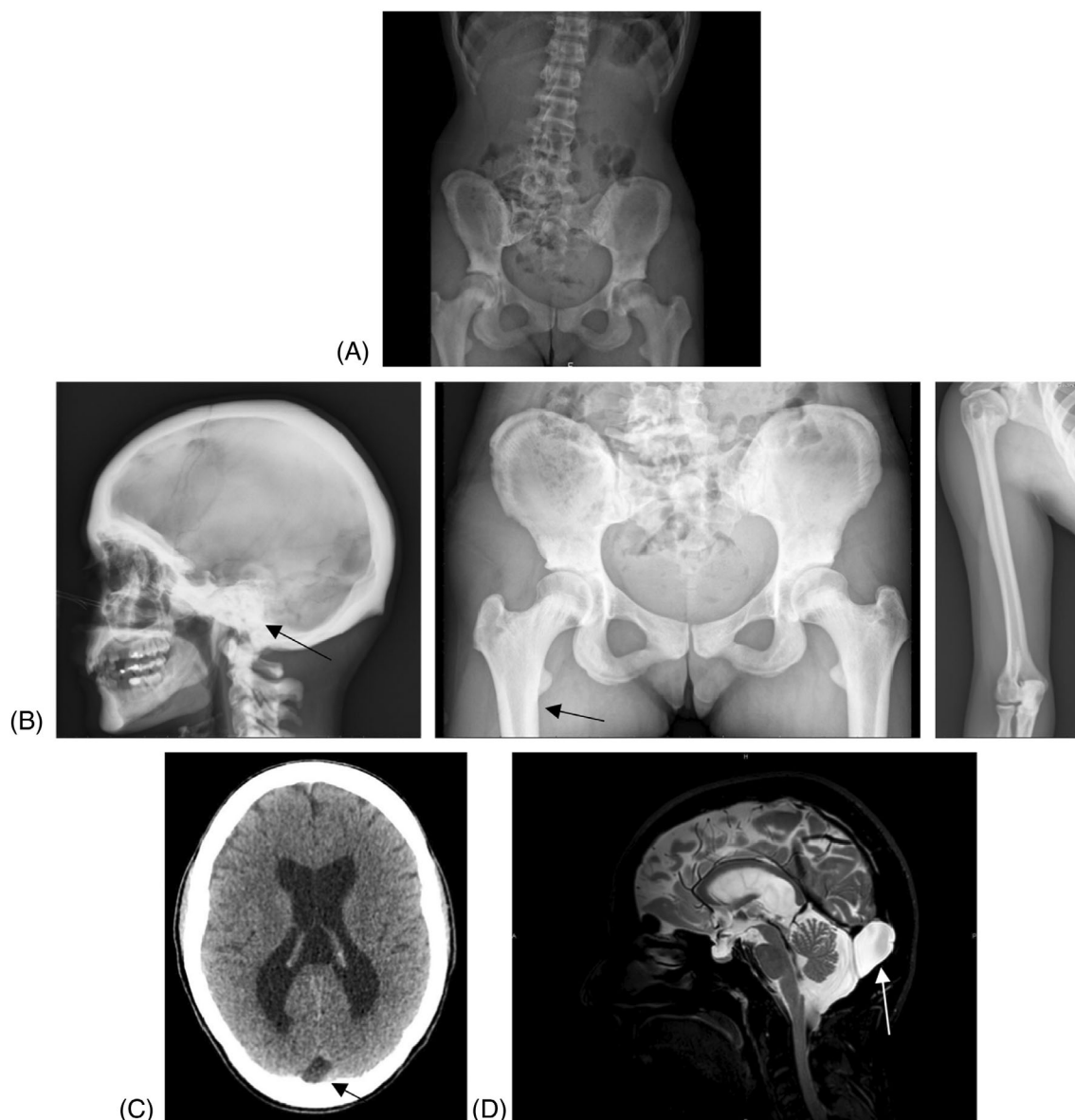
disorder with jaw asymmetry, small ears with plicatured helix and thick lobula, and scars of cutaneous angiomas (trunk and left hand). MRI at 8 months confirmed hemivertebra and showed the spinal cord attached to terminal filum lipoma. Other clinical findings were hypospadias with unilateral cryptorchidism that required surgery. Strabismus, flat foot and splayed toes, and generalized hyperlaxity were also noted. At echography, stable intrahepatic (2.5 cm) and splenic cysts were observed. Later, the boy exhibited oligodontia (only 4 permanent teeth). Echocardiography revealed persistent left superior vena cava, and bradycardia was observed. At school, the boy had concentration problems and was often tired. He also had a diagnosis of minor von Willebrand disease.

During the woman's second pregnancy, ultrasonography revealed cardiac asymmetry and splenic and hepatic cysts in the fetus, considered to be female. The amniocentesis was refused by the mother. Fetal MRI confirmed moderate cerebral ventriculomegaly. The woman delivered a boy at 37 weeks' gestation with eutrophic parameters. The boy experienced respiratory distress and had necrotizing ulcerative enterocolitis at 4 days that was treated with antibiotics. Brain MRI confirmed ventriculomegaly and mega cisterna magna. Hepatic cysts (22–18 mm) were confirmed by ultrasonography after birth and disappeared within the first year; splenic cysts had disappeared at birth. Clinical evaluation revealed hypospadias without cryptorchidism, an umbilical hernia and a left inguinal hernia. The boy had hypertelorism, epicanthus, and thick earlobes and helix like his brother. He underwent heart surgery for an atrial septal defect at age 3 months in a context of persistent left superior vena cava, mild pulmonary arterial hypertension, and bradycardia. Like his brother and mother, he presented osteosclerosis and marked laxity of knees and ankles. Unlike his brother, he does not have hemangioma or hemivertebrae but rather a left 12th costal agenesis (Figure 2B). Oligodontia and school difficulties could not be assessed at this young age.

The father does not have a personal or familial history of bone, dental or heart abnormalities. The family pedigree is shown in Figure S1a (see [Supplementary data](#)). In conclusion, the proband (I.1) and her sons (II.1 and II.3) present common features, all of which are summarized in Table 1.

### 3.2 | Molecular analysis

The osteocondensation phenotype was explored by using a specific targeted gene panel of bone disorders. The molecular analysis revealed the variant NM\_002336.2: c.724T>C, p.(Trp242Arg) in exon 4 of *LRP6* at a heterozygous level for the mother and both her sons (Figure S1a, see [Supplementary data](#)). The healthy mother of the index did not carry the variant. This variant is not described in any public database such as GnomAD or 1000Genomes. This missense variant was not found in HGMD-pro or in ClinVar databases. All predictive analysis software considered this variant as deleterious (CADD score 29.4, Polyphen-2 and Mutation Taster, Revel, MetaSVM, and SIFT) as well as 3D molecular analyses ([Supplementary data](#)). Moreover, the variant is located on the binding site for *SOST* and *DKK1*.<sup>12</sup> This region



**FIGURE 1** Images of proband. X-rays showing complex malformation including scoliosis, left L4 hemivertebra with spina occulta at age 4 (A) and thick cranial vault and cortical bones, especially at metaphysis, confirming the osteocondensation at age 9 (B). CT scan at age 30 (C) and 3D T2-weighted MRI at age 30 (D) showing a retrocerebellar cyst initially diagnosed as mega cisterna magna.

is homologous between *LRP5* and *LRP6* and the identified variant is very close to the p.(Ala242Thr) and p.(Arg266Cys) variants in *LRP5* that are associated with severe endosteal hyperostosis<sup>13</sup> (Figure S1b, see [Supplementary data](#)). Furthermore, as suggested Bourhis et al. study,<sup>12,14</sup> 3D structural analysis has provided evidence that the variant disturbs ligand binding (DKK1, SOST) by distorting the “hydrophobic shutter” formed by W242 and F228 amino acids and also by the involvement of steric clashes. (Figure S1c,d see [Supplementary data](#)). Therefore, we considered this variant as probably pathogenic (class 4) according to HGVS classification. Furthermore, when the second child was born, considered to be a female fetus, a karyotype and fluorescence in situ hybridization of the *SRY* gene confirmed that it was in

fact a male. Considering syndromic morphological abnormalities without a clear orientation, we first used comparative genomic hybridization array (CGH) analysis for both brothers. The analysis showed no structural chromosomal abnormality including no microdeletion of the Y chromosome (arr(1-22)x2,(XY)x1 hg19). Recently, to ensure that no other molecular events could explain the other radiological and clinical abnormalities, we used trio exome sequencing for the youngest brother, quartet genome sequencing and identified only the NM\_002336.2: c.724T>C, p.(Trp242Arg) variant in *LRP6* at the heterozygous level. No other clinically significant variants were found neither in the quartet genome sequencing analysis. Thus, this variant in *LRP6* could be responsible for the entire phenotype.

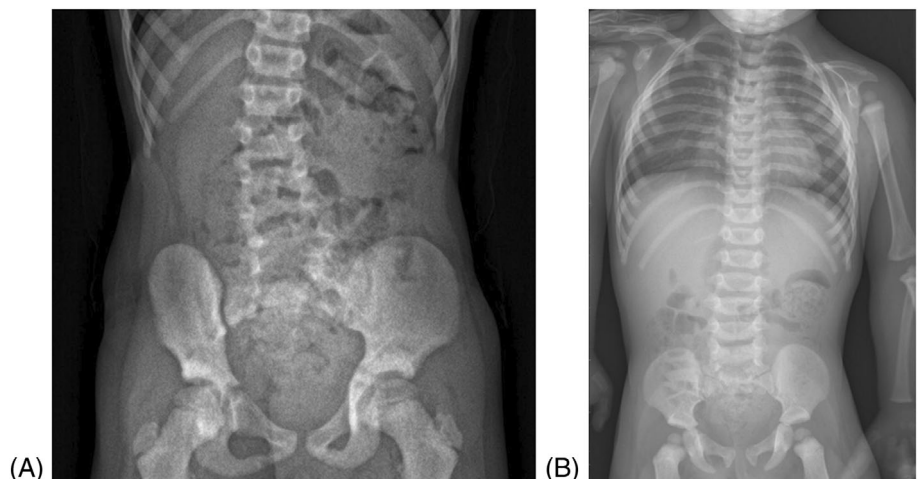
**TABLE 1** Clinical and radiological data for the proband (I.2), her first son (II.1) and second son (II.2).

	II.1	II.2	I.2
<i>LRP6</i> variant	+	+	+
Osteosclerosis	+	+	+
BMD (L1-L4) Z score	+6.1 SD	NA	NA
BMD (femoral neck) Z score	+9.0 SD	NA	NA
BMD (total hip) Z score	+6.4 SD	NA	NA
Oligodontia	+	NA	+
Hemivertebrae	+	+	+
Genital anomalies	+	+	+
Inguinal hernia	+	+	+
Umbilical hernia	–	+	–
Digestive tract	+pyloric stenosis	+necrotizing enterocolitis	–
Hepatic cyst	–	+	NA
Splenic cyst	–	+	NA
persistent left superior vena cava	+	+	+
Dilated brain lateral ventricles	+	+	+
Abnormal posterior fossa	+	–	+
Ophthalmological issues	+strabism	–	–
School difficulties	+	–	–
School difficulties	+	–	–

Note: +: present, –: absent.

Abbreviations: BMD, bone mineral density; NA, not applicable.

**FIGURE 2** X-rays of the woman's children revealed dense bones: (A) the first son (8 years old) showing L5-S1 hemivertebra (right arrow), osteosclerosis area (left arrow) and scoliosis; (B) the second son (2 years old) showing left 12th costal agenesis and dense bones.



## 4 | DISCUSSION

Here, we report the identification of a novel heterozygous variant in *LRP6* in a family with a complex and unusual phenotype. In the first description of clinical signs associated with *LRP6*, the high bone mass phenotype was mild as compared with the phenotype of this family,<sup>1,2,10</sup> and in all cases, oligodontia was observed. Unexpectedly, the affected members of this family did not have torus palatinus or exostoses, which are common in high bone mass related to *LRP5* and *LRP6*.<sup>1,2,10</sup> Also, the two brothers presented hepatic and splenic cysts

that had already been reported associated with *LRP5* in polycystic syndrome (OMIM 617875). Moreover, mice with *lrp6* knockout had macroscopic cystic kidneys.<sup>8</sup> The phenotype of this family confirms that the formation of cysts may be related to imbalanced Wnt signaling. Moreover, *LRP6* is involved in genital organ development because *lrp6*-knockout mice did not have external genitalia.<sup>8</sup> However, further studies are needed to understand the mechanism of *LRP6*-mediated cyst formation and genital anomalies. In addition, *LRP6* is involved in cardiac development, but the persistent left superior vena cava is currently unexplained.<sup>15</sup>

Structural analysis of the *LRP6* interaction shows that *DKK1* and *SOST* interact with *LRP6* via the epidermal growth factor helix-like E1 domain and specifically through a specific YWTD motif, including residue W242.<sup>12</sup> Here, the missense variant, located in a conserved binding site of the first  $\beta$ -propeller motifs, may lead to an alteration or disruption of *DKK1* and *SOST* binding to *LRP6*. In the absence of these two inhibitors, the Wnt signaling pathway is overactivated, thus increasing bone formation. Wnt9B also binds specifically to the E1 domain of *LRP6*; this W242R variant changing a hydrophobic aromatic residue to a dibasic residue probably modifies the affinity of this ligand for its receptor.<sup>14</sup> Wnt9B is involved in several developmental processes, including regulation of cell fate and patterning during embryogenesis. Therefore, it could have an important impact on organ development that needs further investigation. Although this region is strictly conserved between *LRP5* and *LRP6*,<sup>12</sup> the signaling pathways activated by *LRP6* are very different from those of *LRP5*.<sup>16</sup> *LRP6* is involved in multiple signaling cascades apart from Wnt/ $\beta$ -catenin, such as non-canonical Wnt signaling, GPCR signaling, cell cycle-related signaling, and Hippo signaling.<sup>16</sup> These multiplicities of signaling pathways could explain the atypical and more severe phenotype we observed in this family, including dilated brain lateral ventricles and mega cisterna magna. More studies are needed to understand the complexity of *LRP6* signaling during development and diseases, especially that leading to the regulation of cellular activities independent of canonical Wnt/ $\beta$ -catenin signaling.

#### AUTHOR CONTRIBUTIONS

The conception and design of the study (MF, CC), acquisition of data (CD, MF, CC), analysis, and interpretation of data (AP, CD, VCD, MF, CC). Drafting the article or revising it critically for important intellectual content: all authors.

#### ACKNOWLEDGMENTS

The authors are grateful to the patients of this family for participating to the study.

#### CONFLICT OF INTEREST STATEMENT

The authors declare no conflicts of interest.

#### PEER REVIEW

The peer review history for this article is available at <https://www.webofscience.com/api/gateway/wos/peer-review/10.1111/cge.14501>.

#### DATA AVAILABILITY STATEMENT

The data that support the findings will be not available following an embargo from the date of publication to allow for commercialization of research findings.

#### REFERENCES

- Whyte MP, McAlister WH, Zhang F, et al. New explanation for autosomal dominant high bone mass: mutation of low-density lipoprotein receptor-related protein 6. *Bone*. 2019;127:228-243.
- Brance ML, Brun LR, Cócocar NM, et al. High bone mass from mutation of low-density lipoprotein receptor-related protein 6 (*LRP6*). *Bone*. 2020;141:115550.
- Pickering ME, Ltaief-Boudrigua A, Feurer E, Collet C, Chapurlat R. A new *LRP6* variant and Camurati-Engelmann-like disease. *Bone*. 2021;143:115706.
- MacDonald BT, Semenov MV, Huang H, He X. Dissecting molecular differences between Wnt coreceptors *LRP5* and *LRP6*. *PLoS One*. 2011;6(8):e23537.
- Riddle RC, Diegel CR, Leslie JM, et al. *Lrp5* and *Lrp6* exert overlapping functions in osteoblasts during postnatal bone acquisition. *PLoS One*. 2013;8(5).
- Ren Q, Chen J, Liu Y. *LRP5* and *LRP6* in Wnt signaling: similarity and divergence. *Front Cell Dev Biol*. 2021;9:670960.
- Kelly OG, Pinson KI, Skarnes WC. The Wnt co-receptors *Lrp5* and *Lrp6* are essential for gastrulation in mice. *Development*. 2004;131(12):2803-2815.
- Alrefaei AF, Abu-Elmagd M. *LRP6* receptor plays essential functions in development and human diseases. *Genes*. 2022;13(1):120.
- Mani A, Radhakrishnan J, Wang H, et al. *LRP6* mutation in a family with early coronary disease and metabolic risk factors. *Science*. 2007;315(5816):1278-1282.
- Whyte MP, Mumm S, Baker JC, et al. *LRP6* high bone mass characterized in two generations harboring a unique mutation of low-density lipoprotein receptor-related protein 6. *JBMR Plus*. 2023;7(4):e10717.
- Huybrechts Y, Mortier G, Boudin E, Van Hul W. WNT signaling and bone: lessons from skeletal dysplasias and disorders. *Front Endocrinol*. 2020;11:165.
- Bourhis E, Wang W, Tam C, et al. Wnt antagonists bind through a short peptide to the first  $\beta$ -propeller domain of *LRP5/6*. *Structure*. 2011;19(10):1433-1442.
- Gregson CL, Wheeler L, Hardcastle SA, et al. Mutations in known monogenic high bone mass loci only explain a small proportion of high bone mass cases. *J Bone Miner Res*. 2016;31(3):640-649.
- Bourhis E, Tam C, Franke Y, et al. Reconstitution of a Frizzled8-Wnt3a-*LRP6* signaling complex reveals multiple Wnt and *Dkk1* binding sites on *LRP6*. *J Biol Chem*. 2010;285(12):9172-9179.
- Li J, Li C, Liang D, et al. *LRP6* acts as a scaffold protein in cardiac gap junction assembly. *Nat Commun*. 2016;7:11775.
- Jeong W, Jho EH. Regulation of the low-density lipoprotein receptor-related protein *LRP6* and its association with disease: Wnt/ $\beta$ -catenin signaling and beyond. *Front Cell Dev Biol*. 2021;9:714330.

#### SUPPORTING INFORMATION

Additional supporting information can be found online in the Supporting Information section at the end of this article.

**How to cite this article:** Previdi A, Dubourg C, Cormier Daire V, Fradin M, Collet C. Novel variant in *LRP6* associated with unusual and severe clinical presentation: Case report. *Clinical Genetics*. 2024;105(6):666-670. doi:10.1111/cge.14501